



# Neonatal Male Circumcision:

Techniques, Considerations, and  
Complications

Brittany McQuain, NNP-BC



# Today's Focus

- Gomco vs. Plastibell device
- Indications
- Procedure basics and consent
- Complications



# Neonatal Circumcision

Surgical removal of foreskin  
(prepuce)

One of the most common procedures  
worldwide

Performed within first few days of life

Pediatricians, OBs, family physicians,  
and trained neonatal providers

# Historical Background

- Evidence of circumcisions dating back to >4,000 years ago (ancient Egypt)
- Religious significance
- More prominent in Western medicine in early 20<sup>th</sup> century
- US rates are about 60-80%
- Practice varies globally due to cultural, religious, and medical factors
- Remains ethically and culturally controversial with variability in practice worldwide

# Current Guidelines

- Major US medical organizations (AAP, CDC, AUA) state that benefits outweigh risks
- Universal circumcisions are NOT recommended, should be parental decision
- Parents need to receive unbiased counseling about risk, benefits, alternatives
- Procedure should be performed by a trained provider with proper technique and anesthesia
- Circumcision should not be performed if contraindications present (anatomy, bleeding disorders etc.)

# Contraindications

- Hypospadias/Epispadias (foreskin used in surgical correction)
- Buried penis and micropenis
- Chordee
- Penoscrotal webbing
- Ambiguous genitalia
- Bleeding disorders
- Clinical instability
- Prematurity

# Circumcision Techniques

- Gomco
- Plastibell
- Mogen, surgical free hand, other clamp techniques (not discussed today)

# Procedure Overview

- Prep + Sterile field
- Anesthesia (ring block) allow 3-5 minutes
- Dilate opening and adhesion release
- Crush clamp for 1 minute
- Create a dorsal slit and exposure of glans
- Device sizing and placement
- Complete in accordance to chosen method



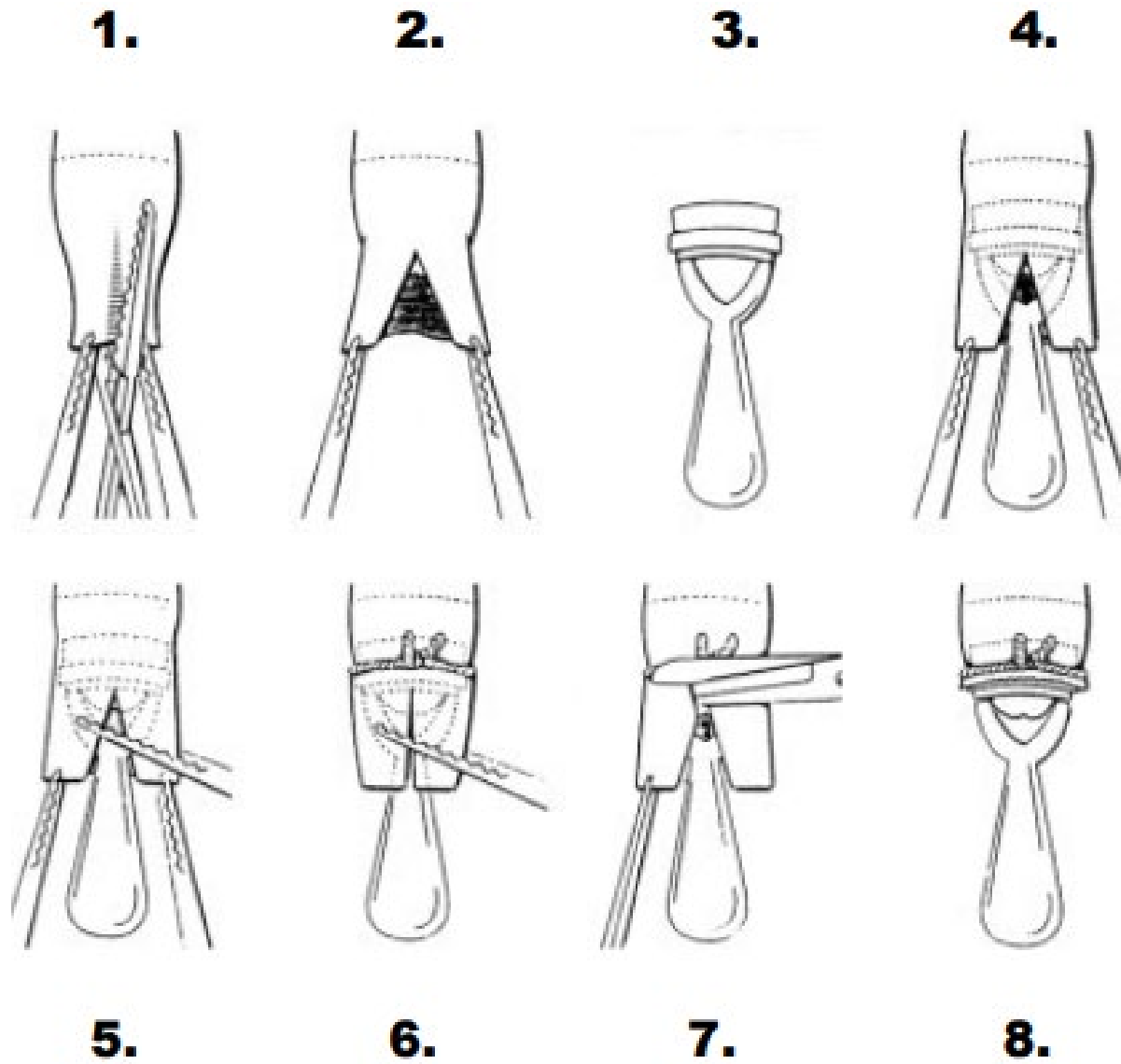
# Pain Management and Anesthesia

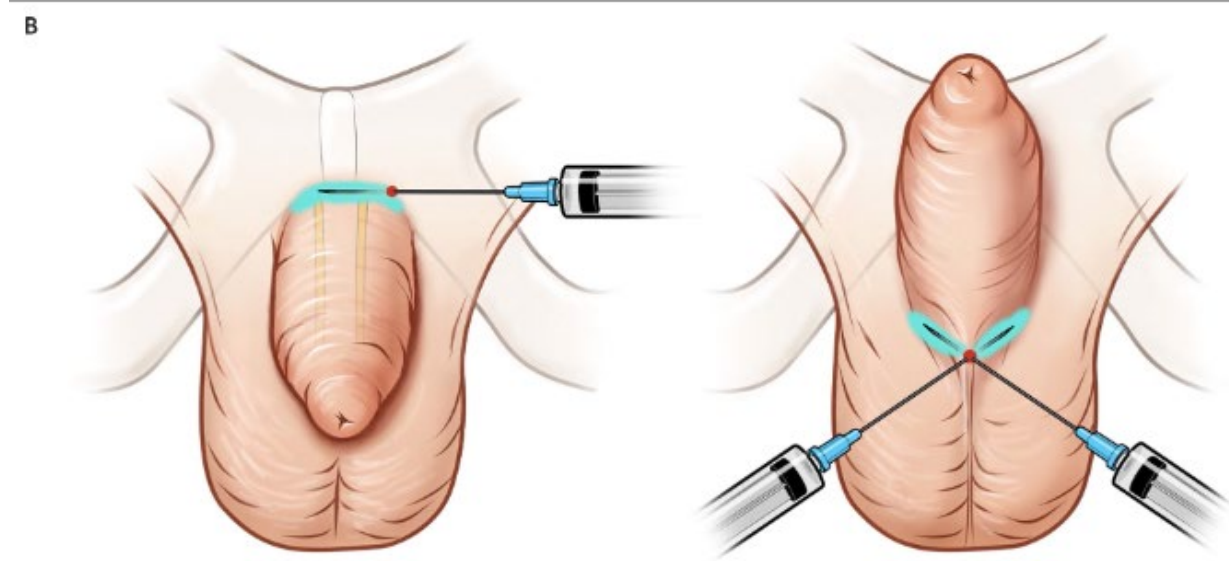
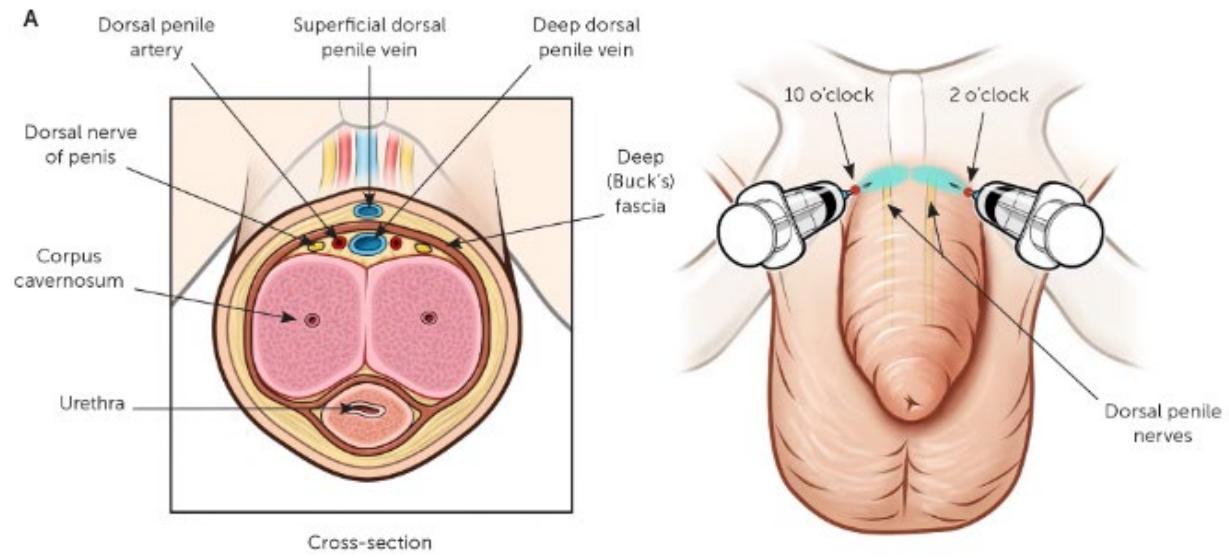
- Circumcisions ARE painful
- Dorsal penile nerve block (DPNB)
- Ring Block
- Oral sucrose
- Acetaminophen



# Pain Management and Anesthesia

- Ring block has been shown to be superior
- Acetaminophen is more effective after procedure
- Pain peaks once analgesic wears off
- Giving acetaminophen too early will not adequately cover peak pain effectively
- Most effective timing is 1-2 hours after





# Plastibell

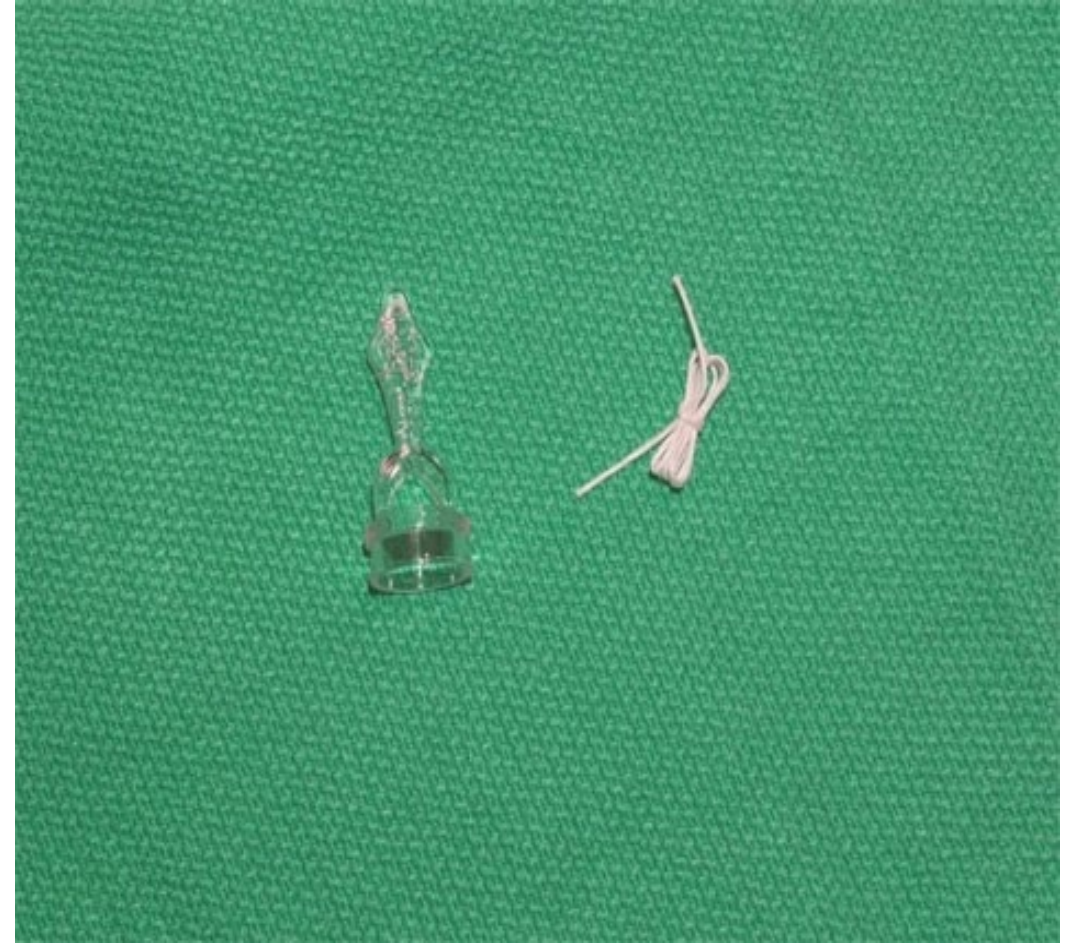

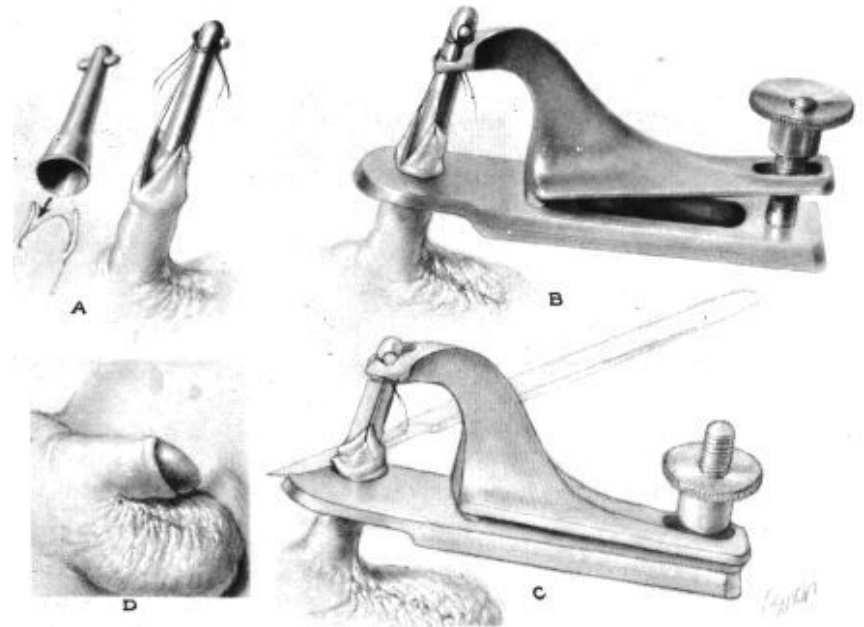
Image retrieved from [Plastibell Technique | Newborn Nursery | Stanford Medicine](#)



# Plastibell

- Introduced in mid 1950s
- Induces circumcision by necrosis
- Uses plastic ring and ligature
- Advantage hemostasis with ligature
  - Fewer bleeding events
- Can have retention and migrations 6-11%
- No after care
- Lower family satisfaction rates due to delayed separation and perceived pain

# Gomco





# Gomco

- Introduced in 1935
- Induces circumcision by crush injury and excision of prepuce
- Slightly longer procedure time
- Increased risk of bleeding
- Vaseline and gauze x5 days after procedure
- Higher parent satisfaction

# Quick Comparison

## **Gomco**

- Crush + excision
- Higher bleeding risk
- Excessive skin removal risk
- Vaseline after care
- Higher parent satisfaction

## **Plastibell**

- Ischemic necrosis
- Lower bleeding risk
- Minimal after care
- Retention/Migration risk
- Lower parent satisfaction

# Benefits

- **UTI Prevention**
  - 90% reduction in risk of acute pyelonephritis in healthy boys
  - 10-fold reduction in UTI relative risk (absolute risk is already low)
  - Lifetime UTI risk reduced from 32% to 9%
- **Penile Cancer Prevention**
  - Reduces risk by 67%
  - Adult circumcisions do not protect
- **Reduces penile conditions**
  - Decreased risk of phimosis, paraphimosis, balanoposthitis
- **STI Protection**
  - 35% reduction in HPV
  - Female partner protection (HPV, cervical cancer, other STIs)
  - HIV reduction (this is very skewed to African settings)

# Complications and Considerations

- Complication rates are about 0.2-0.4% when performed by experienced provider
- All age circumcision complication rates are ~4%
- No difference in rates of revision or ER visits between Plastibell and Gomco
- Infection rates are about 1 in 500
- Significant bleeding in 0.1%
- Other common minor complications
  - Bleeding (especially > 44wks and > 5 days)
  - Infection
  - Adhesions

# Retracting Remaining Skin

- Adhesions are common post-procedure
- Important to do retractions once circumcision is healed
- Minor re-adhesion occurs in up to 70-80%
- Adhesions can appear weeks to months later
- Many adhesions resolve with conservative management and daily retraction
- Educate families (and nurses) to “keep the glans visible” with each diaper change for 6mo+



# Getting Comfy with “C.I.R.C.” Consent

## Choice

- Explain that parents have a choice and this is an elective procedure, we cannot guarantee the outcome

## Inform/Indications

- Upper body swaddled, placed on a board with soft restraints, numbed with lidocaine that lasts 1-2hrs, sugar water and Tylenol, some bleeding expected, may not eat well after
- Lower UTI risk in infancy, lower risk of penile conditions and infections, some benefits for female partners



## Risks

- Bleeding, infection, glans injury, revision (too much or too little), rare serious complications, risk of abandonment
- Device specific risks (Plastibell migration, excess skin removal Gomco etc.)

## Care after procedure

- **Gomco** – Vaseline with EVERY SINGLE diaper change x5 days
- **Plastibell** – Allow natural detachment of bell, keep clean
- Expect mild swelling, yellow exudate with healing, no submerging in bath until fully healed within 7 days
- Gentle shaft skin retractions for 6 months

# Meet General Surgery





# References

- Ahmad, I., Tang, J., Khondker, A., Malik, A., Chua, M., Rickard, M., Lorenzo, A. J., & Dos Santos, J. (2024). Evaluating Safety of Ring Versus Clamp Devices in Neonatal Circumcision: A Meta-Analysis. *Journal of pediatric surgery*, 59(10), 161606. <https://doi.org/10.1016/j.jpedsurg.2024.06.015>
- Alsowayan, O. S., Al Zahrani, A. M., Basalelah, J. H., Al Madi, M. K., Al Humam, A. A., Al Otaibi, A. N., AlKhamis, A. A., Fadaak, K. H., Al Suhaibani, S. S., & El Darawany, H. M. (2024). A prospective randomized controlled trial measuring satisfaction and parents stress after Gomco and Plastibell infant circumcision. *Pediatric surgery international*, 40(1), 51. <https://doi.org/10.1007/s00383-024-05633-z>
- American Academy of Family Physicians. (2020). *Newborn circumcision techniques*. *American Family Physician*, 101(11), 680-685.
- American Academy of Pediatrics Task Force on Circumcision. (2012). Male Circumcision. *Pediatrics* 130(3), e756-785. <https://doi.org/10.1542/peds.2012-1990>
- American Urological Association (n.d.). *Circumcision*. <https://www.auanet.org/about-us-uaa-statements/circumcision>
- Centers for Disease Control and Prevention. (2021). Information for healthcare providers: *Male circumcision*. <https://www.cdc.gov/hiv/clinicians/prevention/circumcision.html>
- Mallinger, J. C., Siretskiy, R., Avila, A., Tichauer, J., Rivas, L., Samuels, S., Neville, H., & Levene, T. (2025). Comparative Analysis of Postoperative Outcomes Following Various Neonatal Circumcision Techniques: Mogen Clamp, Gomco Clamp, and Plastibell Device. *The American surgeon*, 91(8), 1263–1266. <https://doi.org/10.1177/00031348251346523>
- Pitts, D., Aponte-Colon, D., & Chalmers, D. (2022). Resolution of post-circumcision penile adhesions in newborns. *Journal of pediatric urology*, 18(2), 183.e1–183.e5. <https://doi.org/10.1016/j.jpurol.2021.12.010>
- Sharara-Chami, R., Lakissian, Z., Charafeddine, L., Milad, N., & El-Hout, Y. (2017). Combination Analgesia for Neonatal Circumcision: A Randomized Controlled Trial. *Pediatrics*, 140(6), e20171935. <https://doi.org/10.1542/peds.2017-1935>
- Simpson, E., Carstensen, J., & Murphy, P. (2014). Neonatal circumcision: new recommendations & implications for practice. *Missouri medicine*, 111(3), 222–230.