

# Critical aortic stenosis

Disclosures

No disclosures

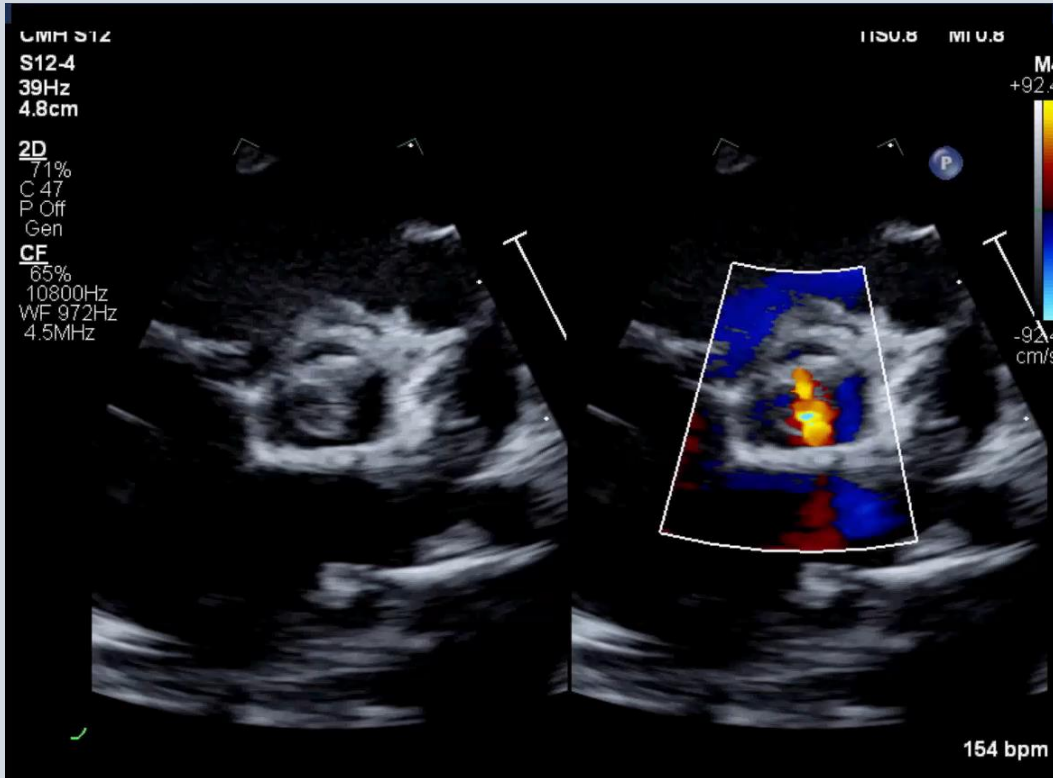
# Objectives

Gain a better understanding of Critical AS in fetal life

Explain the role of fetal cardiology and echo in diagnosing critical AS in a fetus

Learn the different pathways a critical AS patient may take in the management of this cardiac defect

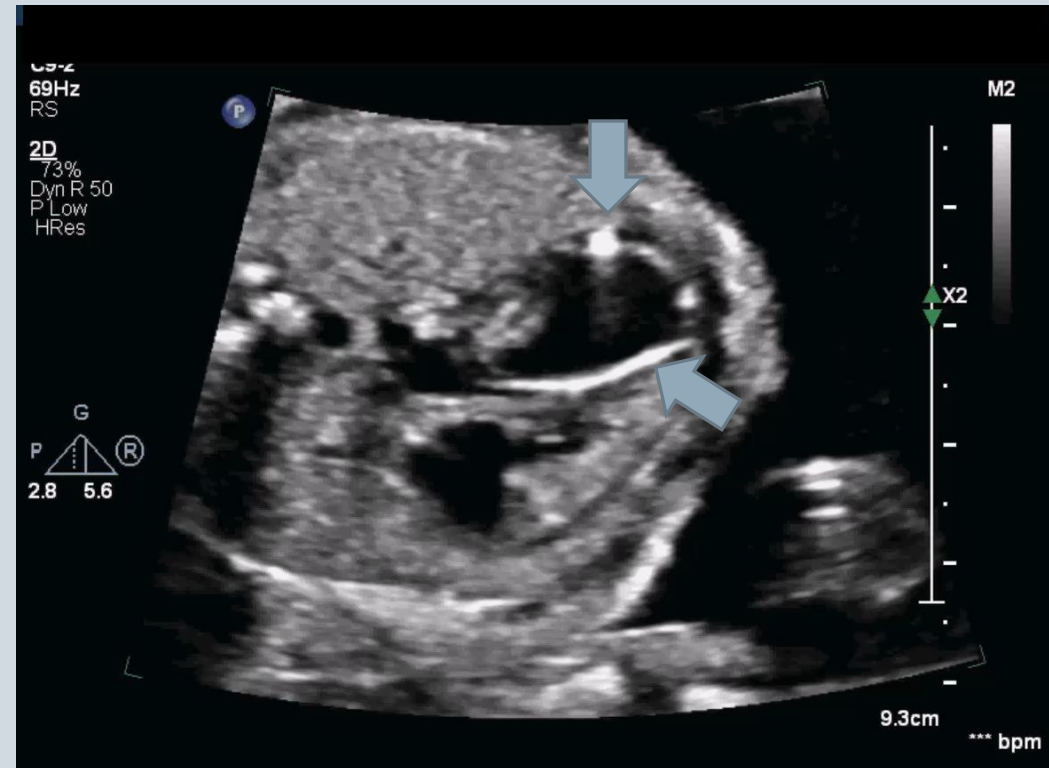
# Aortic stenosis



- Aortic valve stenosis in children is usually due to a congenitally abnormal aortic valve rather than degeneration of a normal valve
- Morphologically, this may be due to
  - Commissural underdevelopment
  - Thickening of the valve leaflets
  - Annular hypoplasia
  - Combination of these elements

# Pathophysiology

- Obstruction to the left ventricular outflow tract results in an increased afterload on the left ventricle
  - In fetal life, mild stenosis of the aortic valve is usually well tolerated
  - In fetuses with critical aortic valve stenosis the left ventricle dilates, contractile function decreases and endocardial fibroelastosis(EFE) often develops



“No flow no grow”

- Decreased blood flow in fetal life can lead to hypoplasia of cardiac structures
- In severe or critical AS the aorta, aortic arch, left ventricle and mitral valve can become hypoplastic by term
  - Can turn an aortic stenosis case into a single ventricle pathway
    - “Hypoplastic left heart variants”
  - This progression of aortic valve stenosis to a situation like hypoplastic left heart syndrome has led to prenatal intervention being considered for affected fetuses

# Prenatal detection Critical cases

- Left ventricle is typically dilated early in gestation with reduced function
- Endocardial fibroelastosis is commonly seen
  - Appears as a bright echogenic lining in the LV
  - Severity may vary
- Patent foramen ovale (PFO) which is right to left in fetal circulation, may be left to right due to severe LV obstruction
  - Can become severely restricted or even intact
  - Pulmonary veins can help determine degree of atrial restriction
- Aortic arch often has retrograde filling
  - Studies have indicated this is a precursor to evolving HLHS

# Why prenatal detection is important

---

- In infants with severe aortic stenosis with severe left ventricular dysfunction and/or underdevelopment of left sided structures; post natal circulation may not be supported
  - Imperative to distinguish if aortic stenosis is considered “critical AS” and needs prostaglandins after birth to keep duct open
  - In some cases, the fetus may benefit from fetal intervention
  - Family and fetus benefit having a plan in place



# The fetal echo

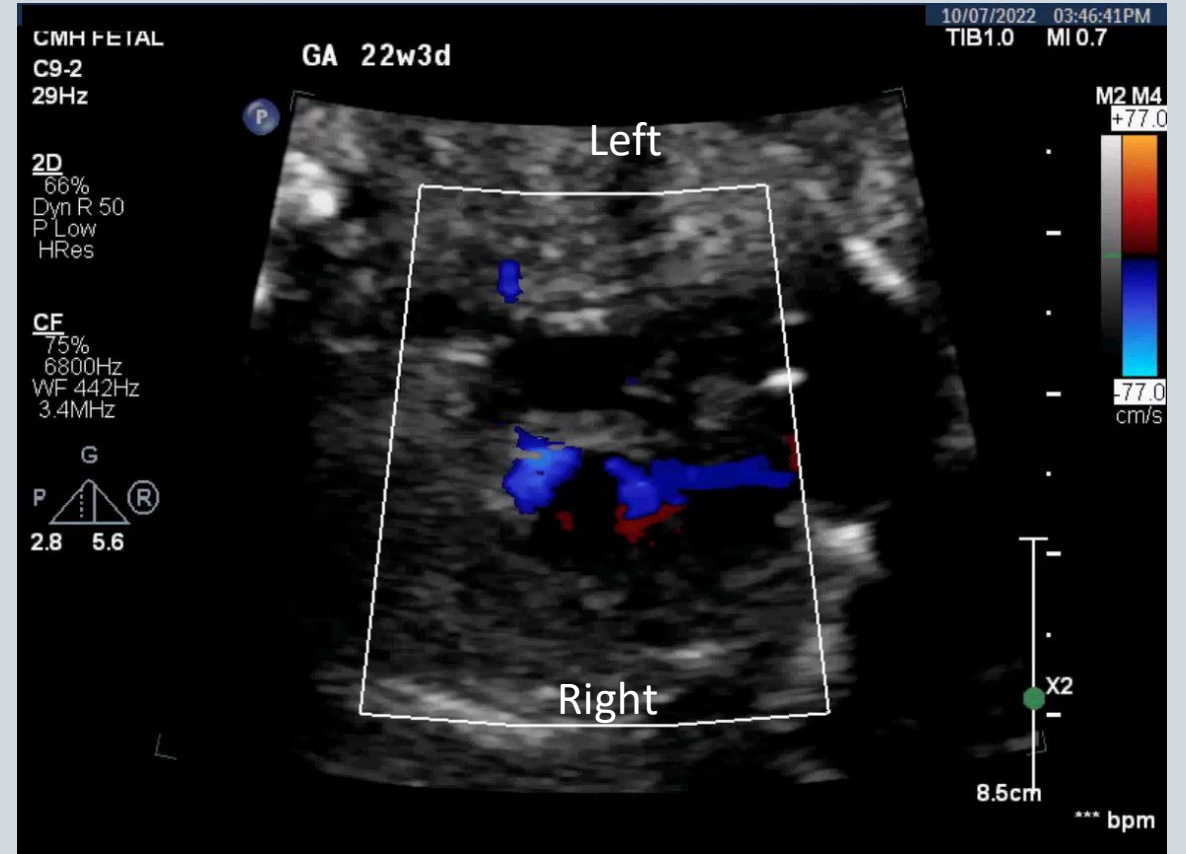
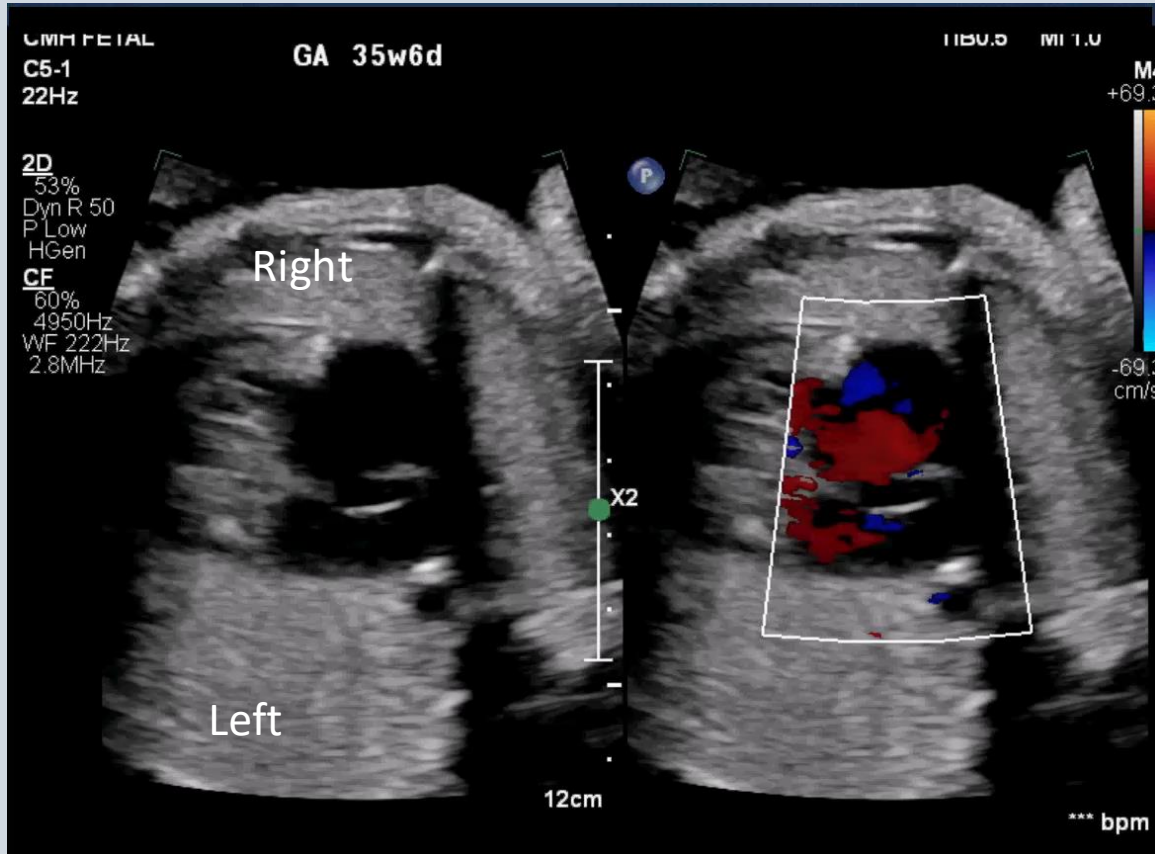
---

- Assessing aortic stenosis
- Diameters of left and right ventricles
- Lengths of right and left ventricles
- Diameters of the mitral and tricuspid annuli
- Severity of mitral valve regurgitation
- Diameters of aortic valve annulus and aortic arch
- Direction of systolic flow in the distal aortic arch (antegrade versus retrograde)
- Pulmonary vein dopplers for VTI
- Patent foramen ovale

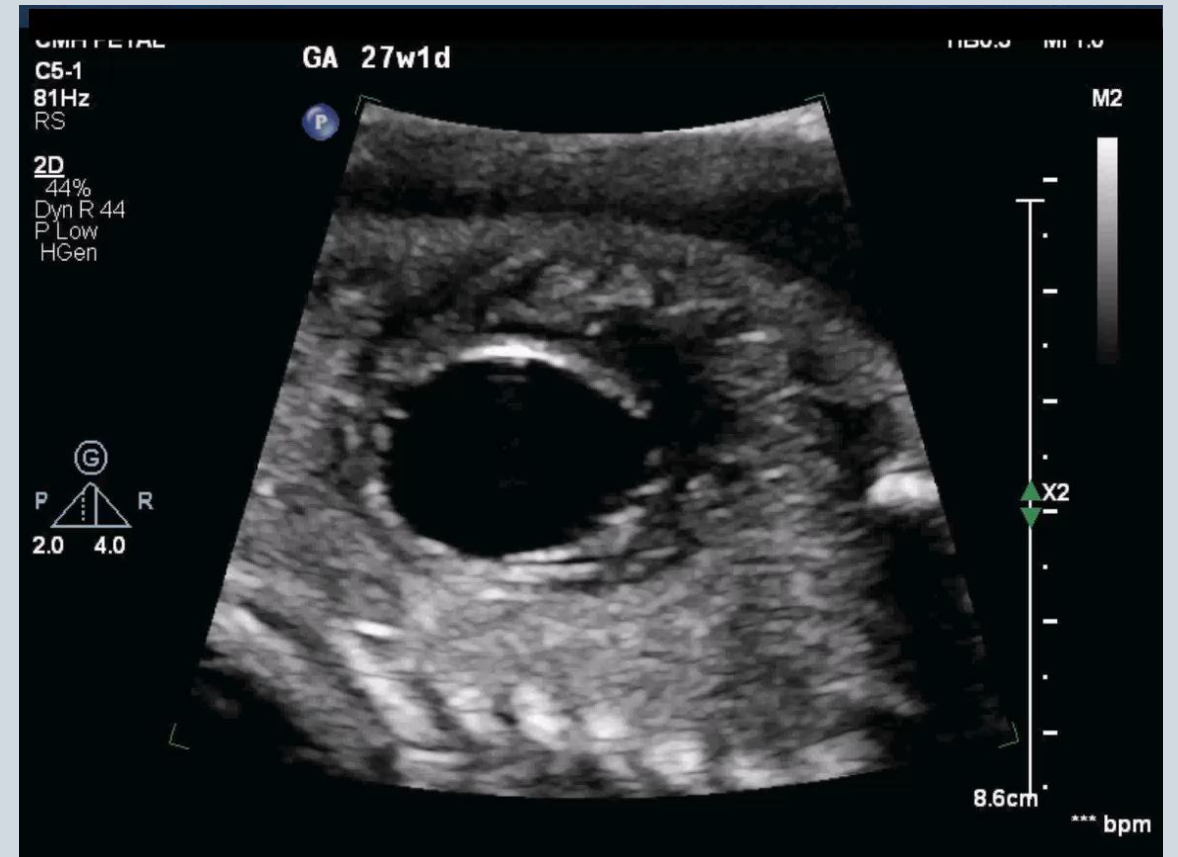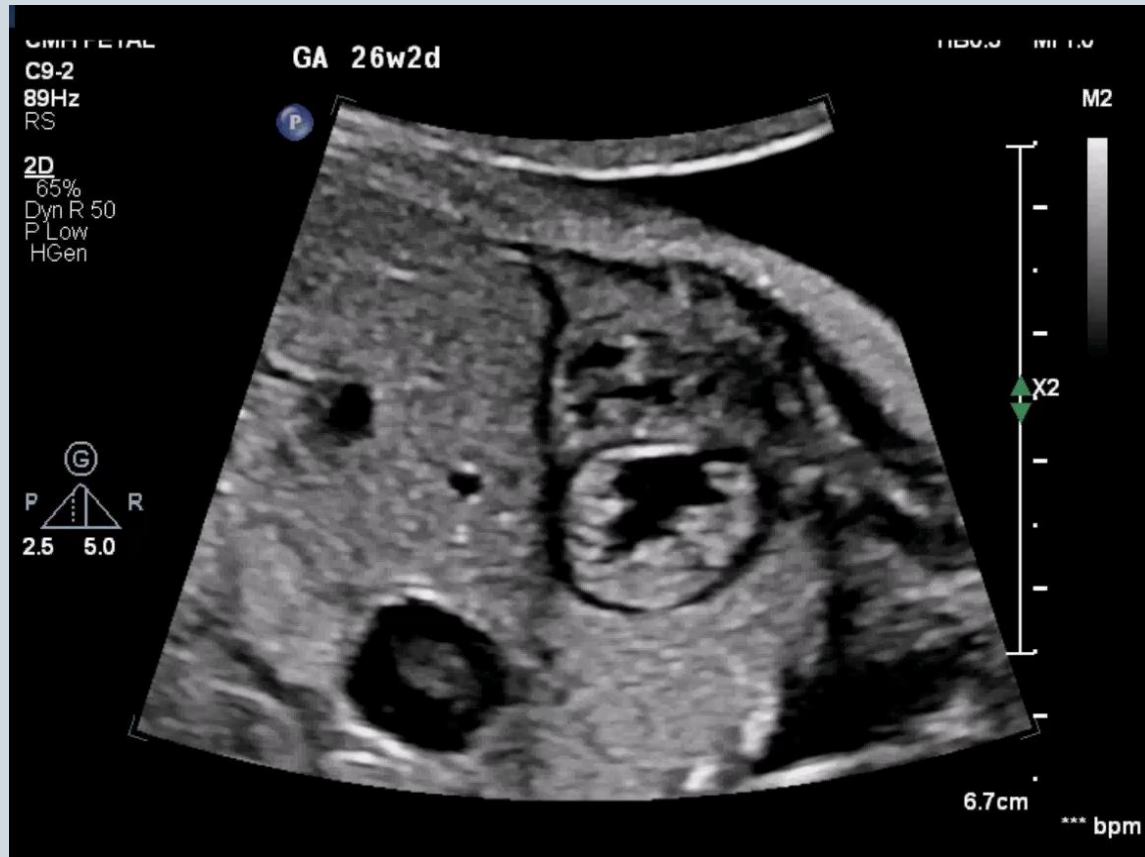# Atrial septum

NORMAL (RIGHT TO LEFT)

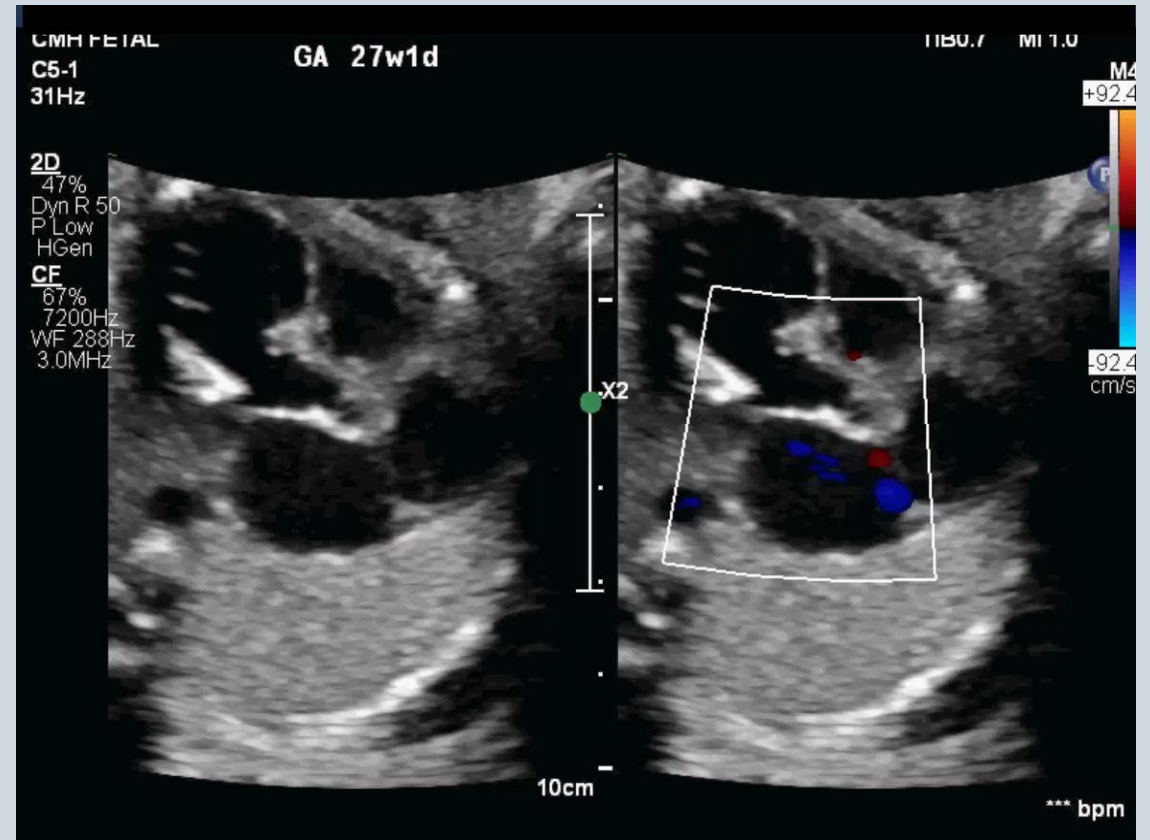
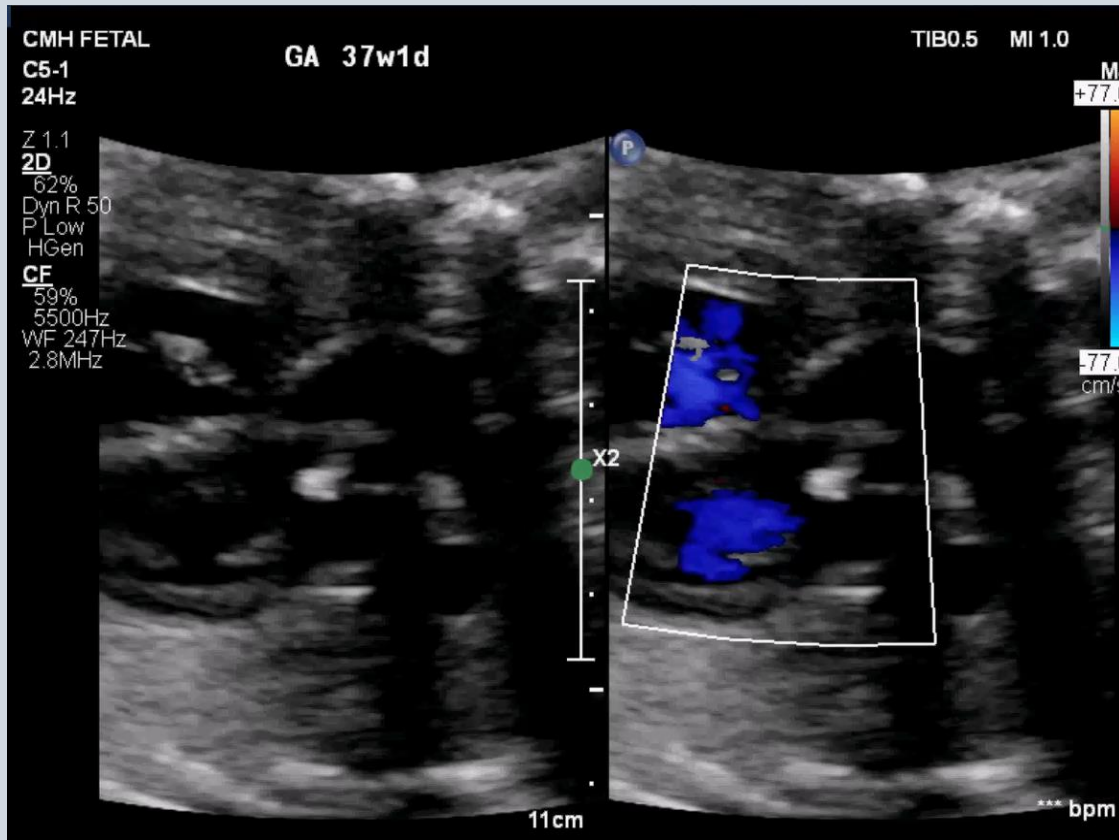
ABNORMAL (LEFT TO RIGHT)



# Function



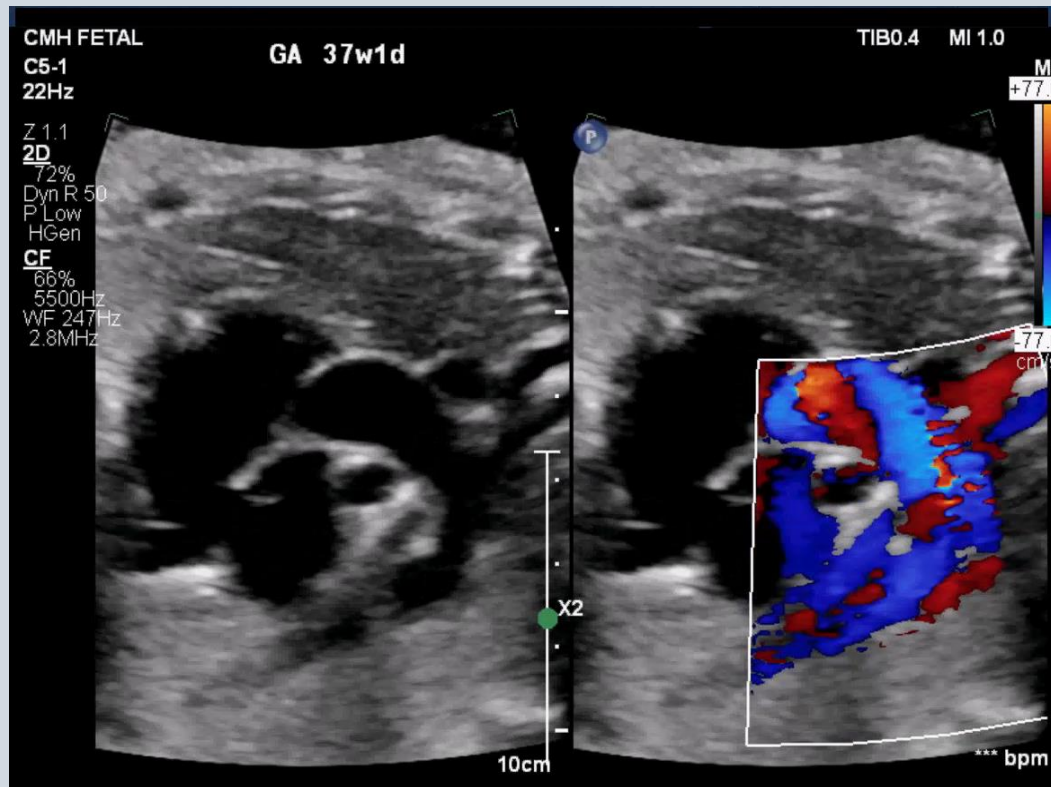
# Aortic stenosis



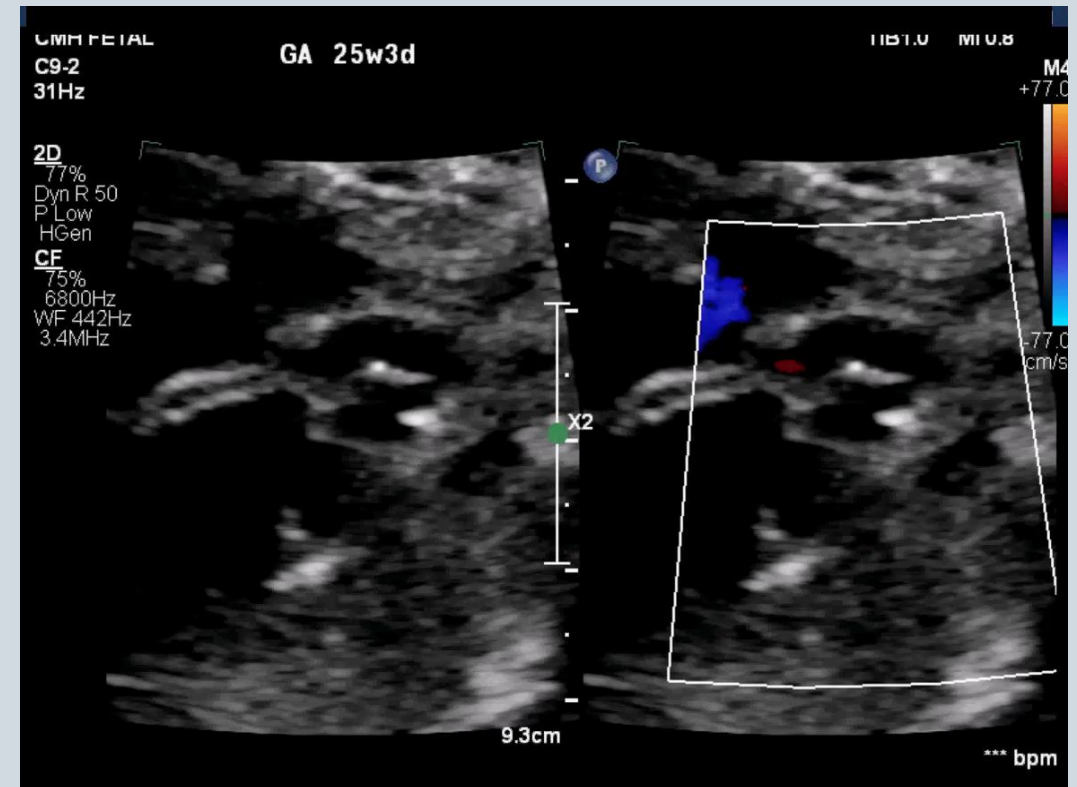


# Aortic arch

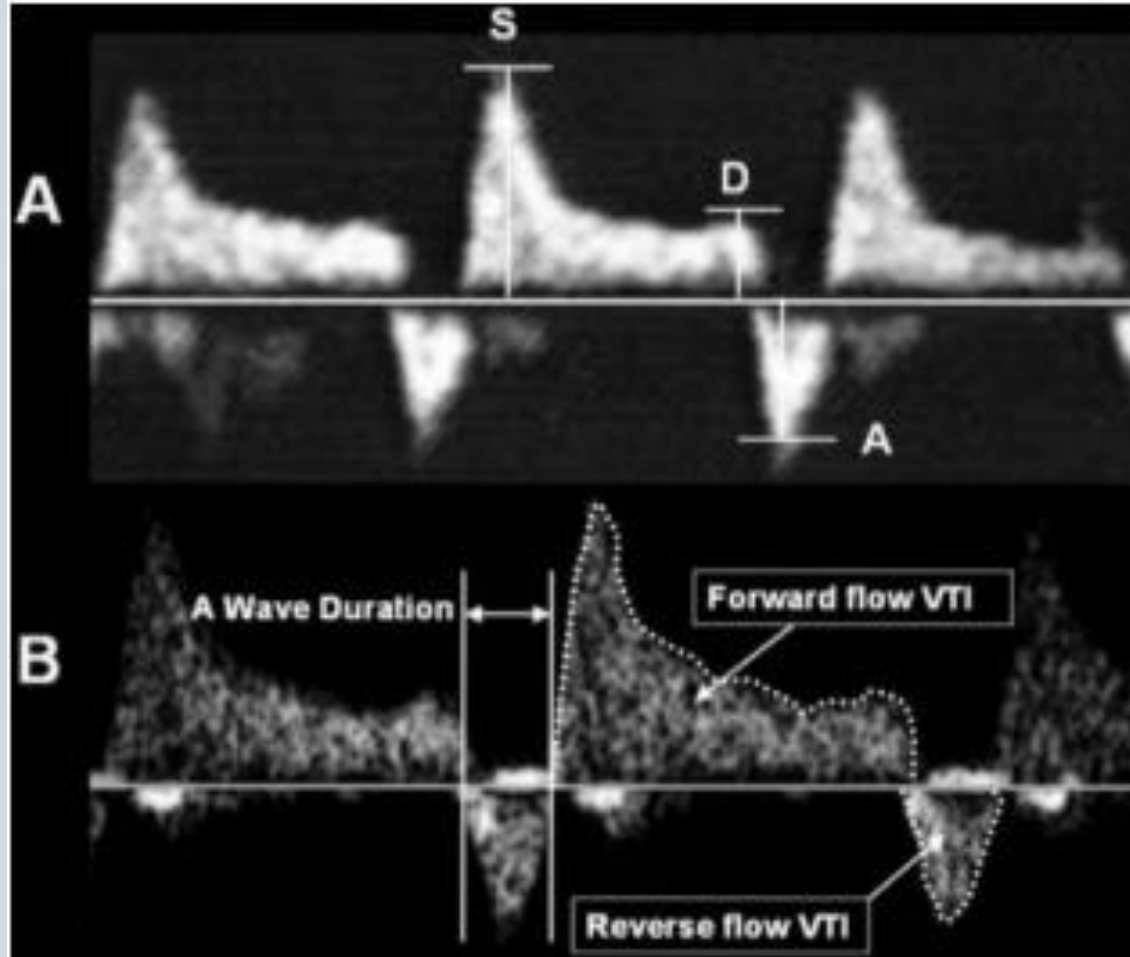
ANTEGRADE FILLING



RETROGRADE FILLING



# Pulmonary vein VTI



- Velocity-time integral
- In the fetus with HLHS, a pulmonary vein VTI  $< 5$  is the strongest predictor of the need for emergent atrial septostomy in the newborn period
  - Dividing forward flow VTI by reverse flow VTI to get ratio
- Predictor if fetal intervention is needed (if additional criteria met)

# Critical aortic stenosis-options

---

- Fetal aortic stent ←
- Comfort care ←
- Single ventricle pathway ←
  - Hybrid → Norwood
- Prenatal aortic valve balloon
- “IMPACT” procedure
  - Immediate postpartum access to cardiac therapy

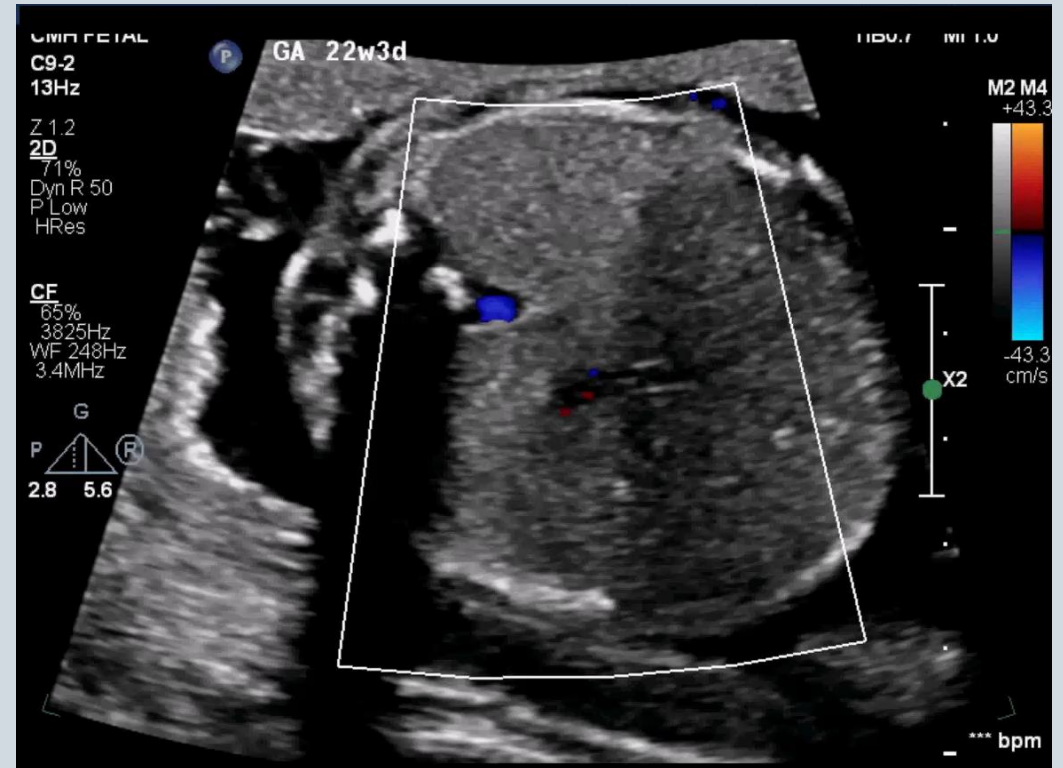
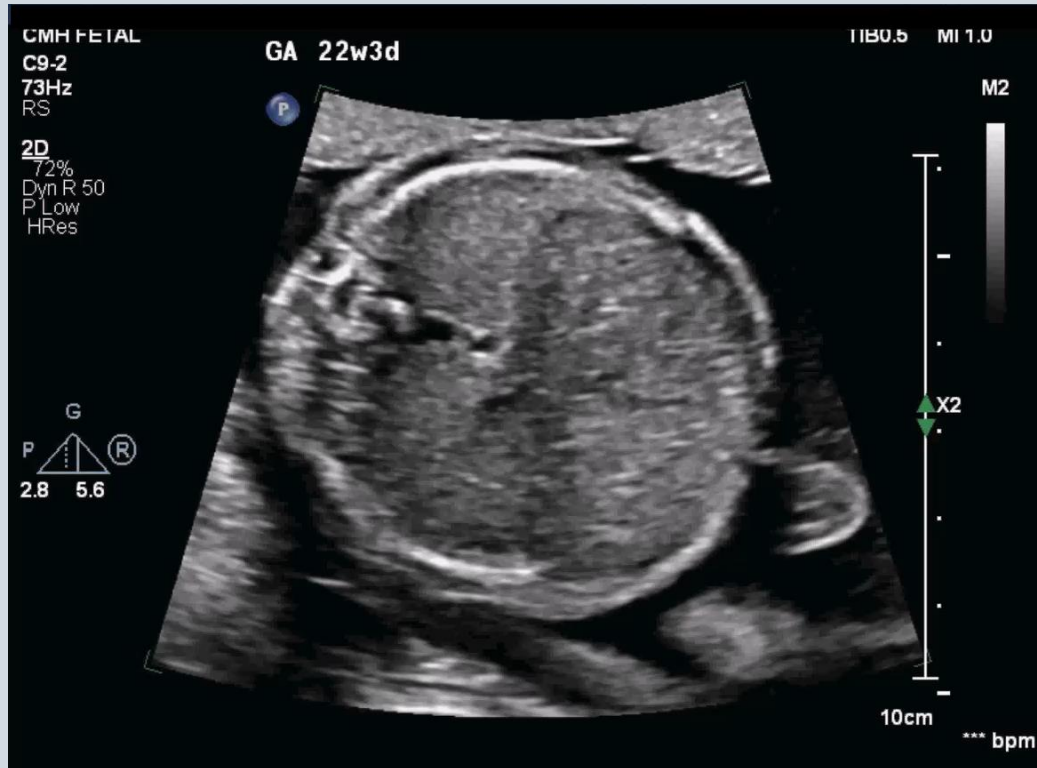# Case #1- Atrial Stent

---

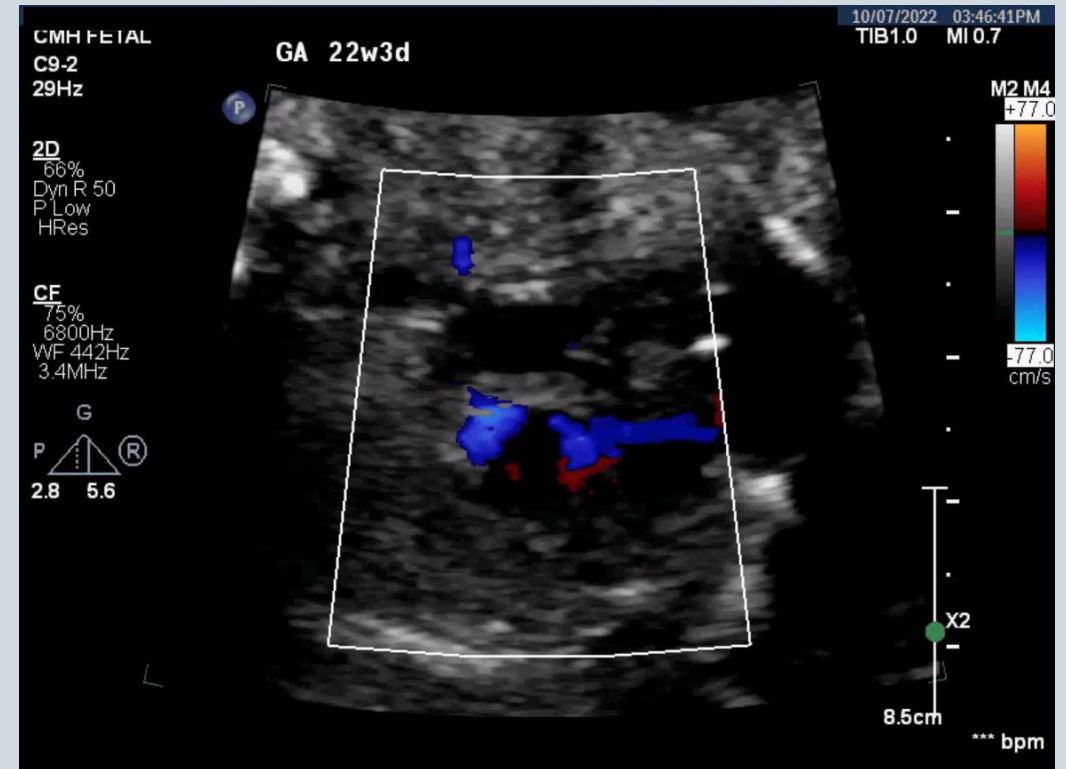
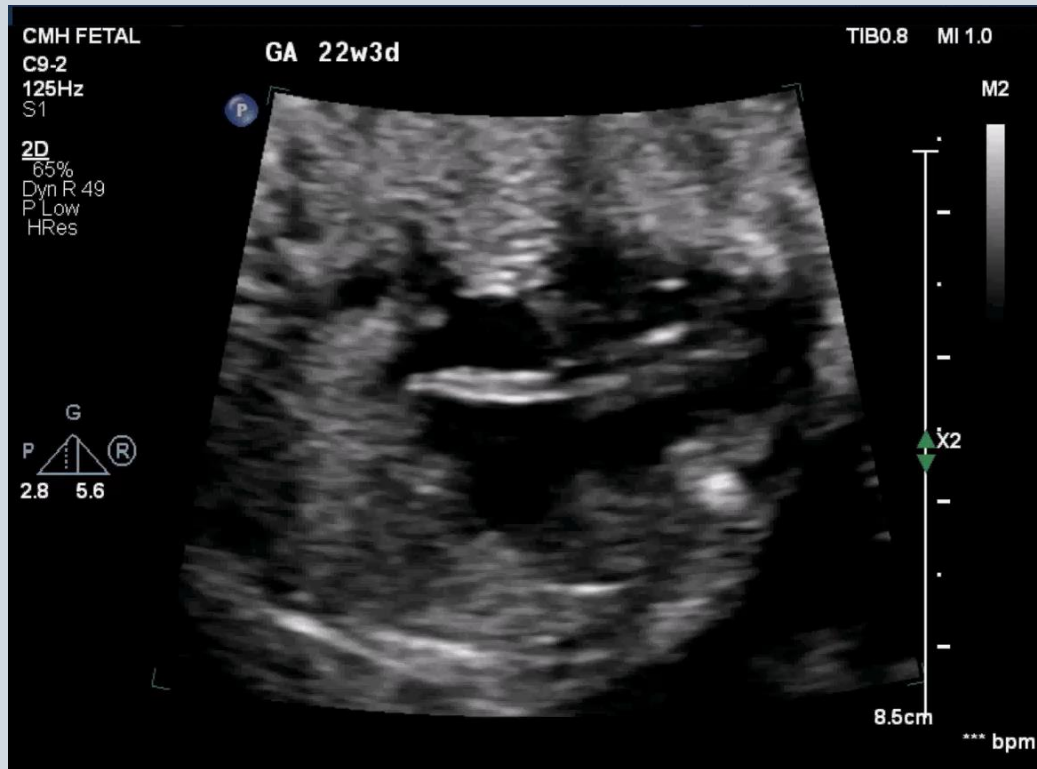- G1 P0
- Singleton gestation at 22 weeks 3 days
- Diagnosis:
  - Critical aortic stenosis with evolving hypoplastic left heart syndrome
  - Restrictive atrial septum



# Initial sweeps

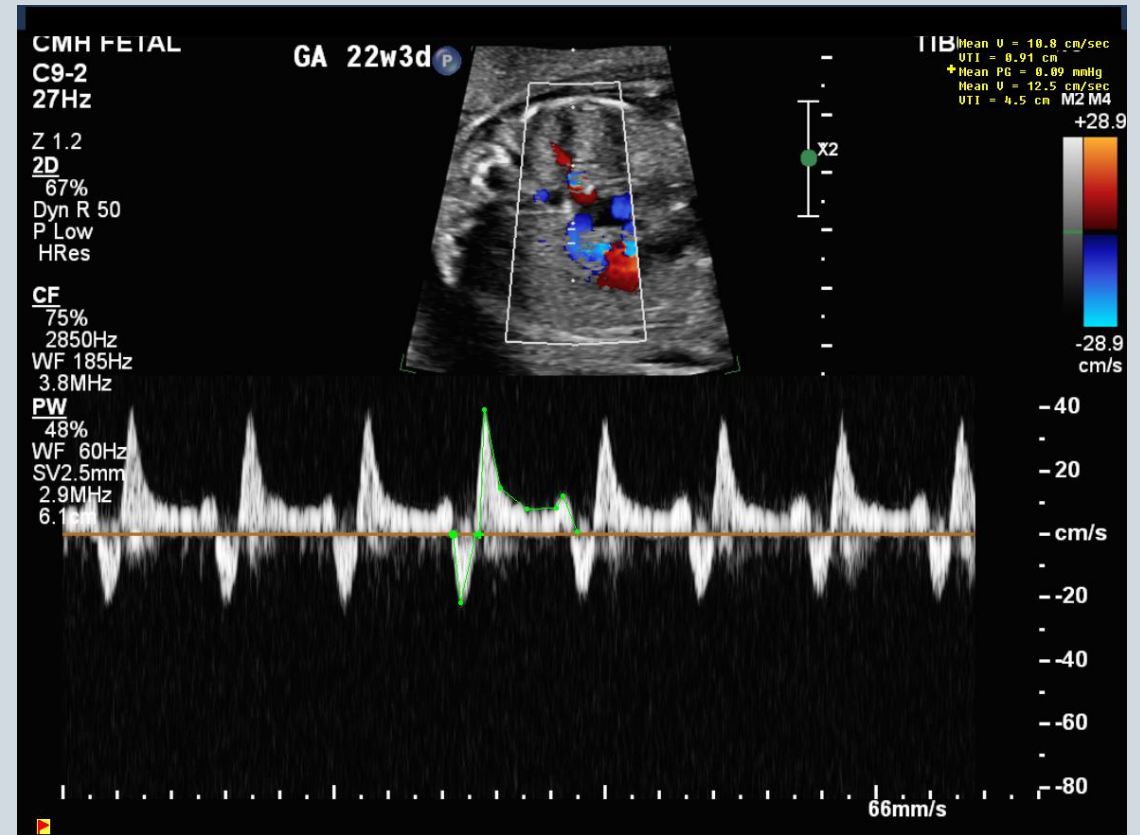
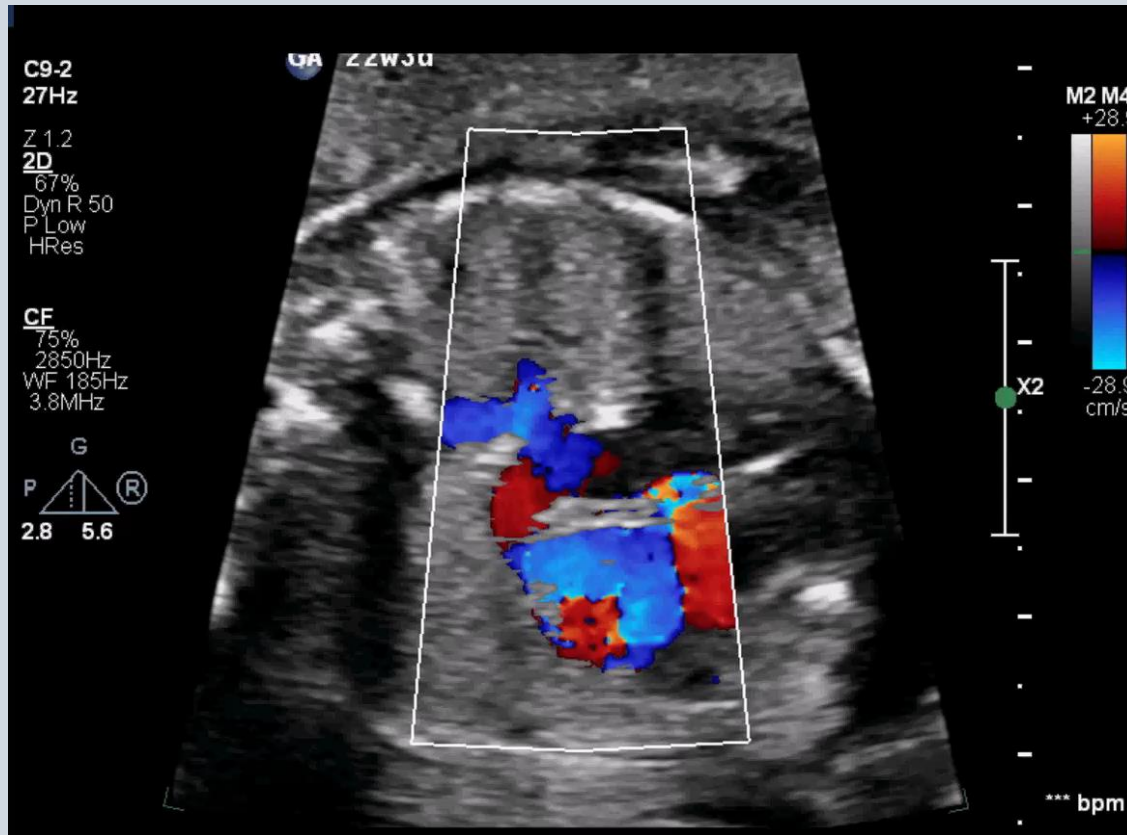


# Atrial septum



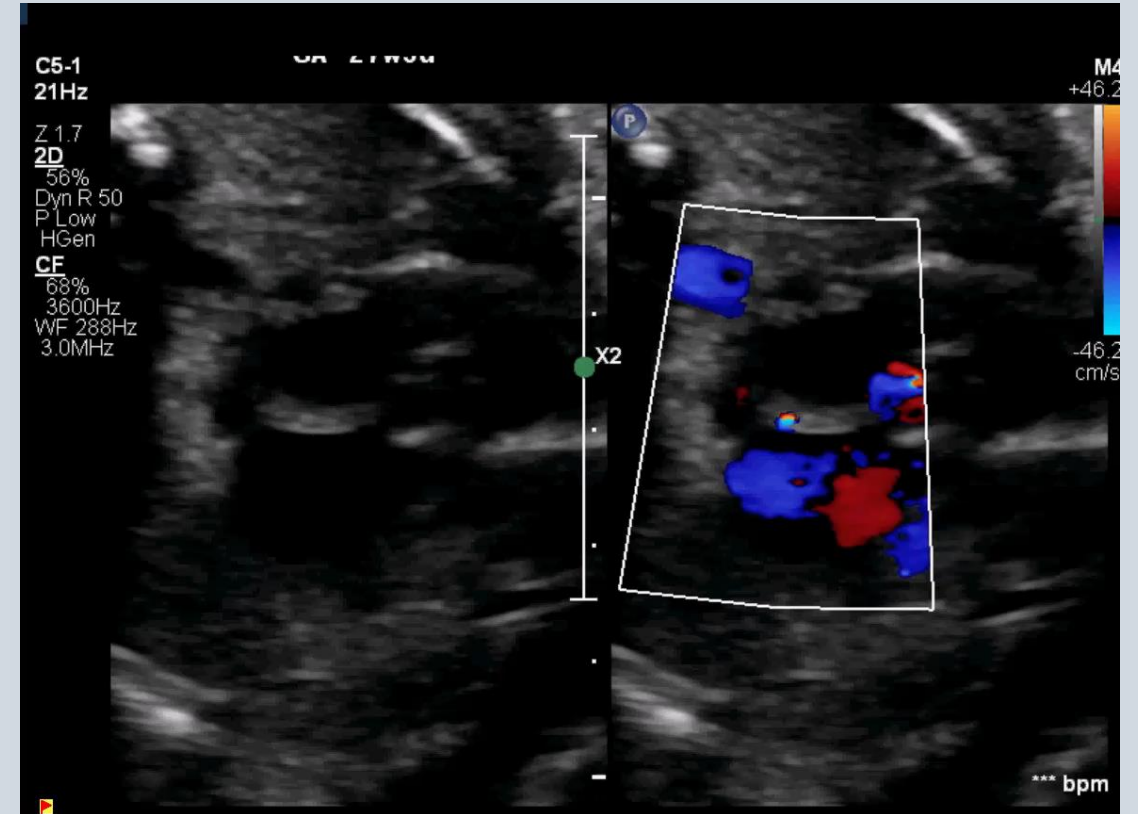
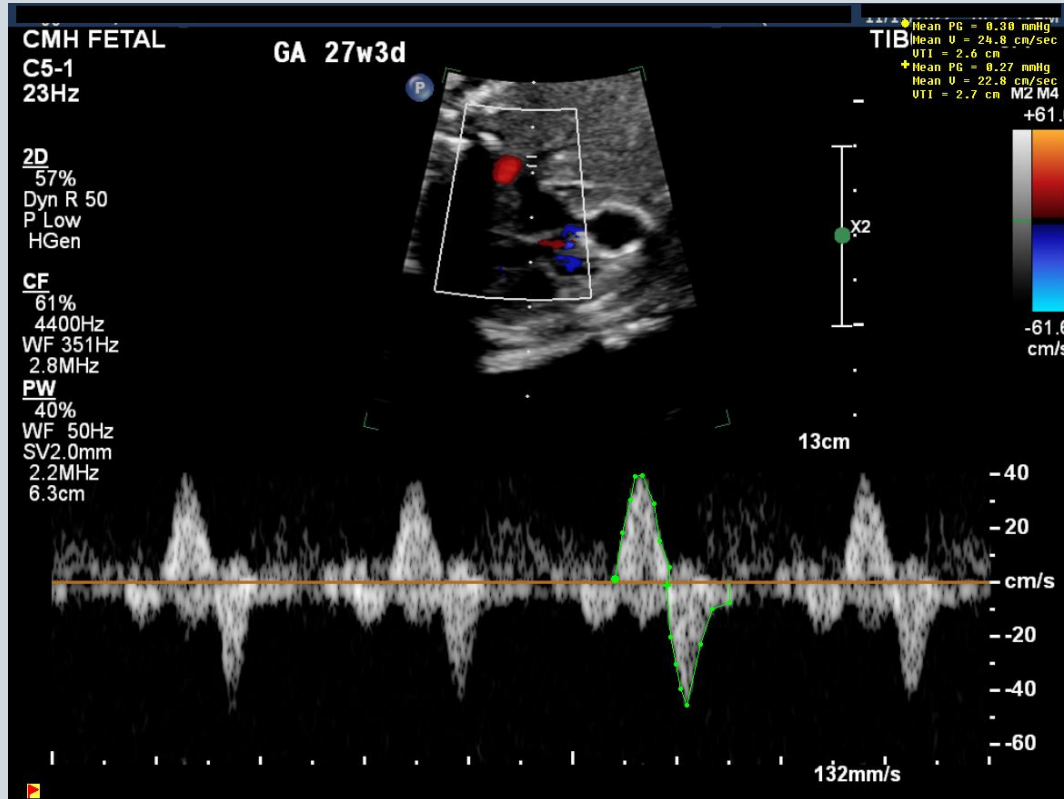
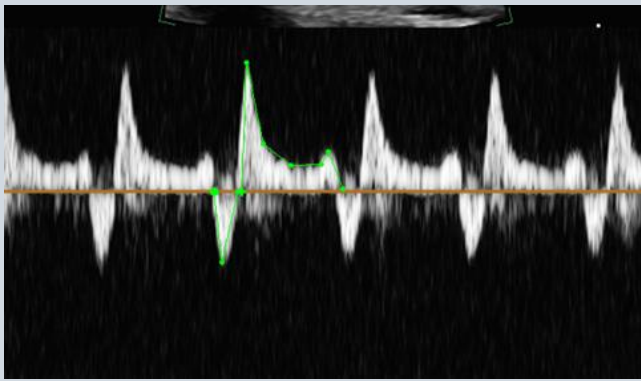
# Pulmonary veins

VTI 4



# 27 weeks 3 days

VTI 2.1





# Criteria for atrial stent

## INCLUSION CRITERIA

- Single gestation
- Agreement to social work assessment
- Documented understanding of the voluntary nature of the intervention
- Severely restrictive or intact atrial septum with **VTI ratio < 3** and/or pulmonary lymphangiectasia on fetal MRI
- Adequate left atrial size for intervention
- No aneuploidy (specifically T13/T18, Turner syndrome, or T21 by amniocentesis)

## EXCLUSION CRITERIA

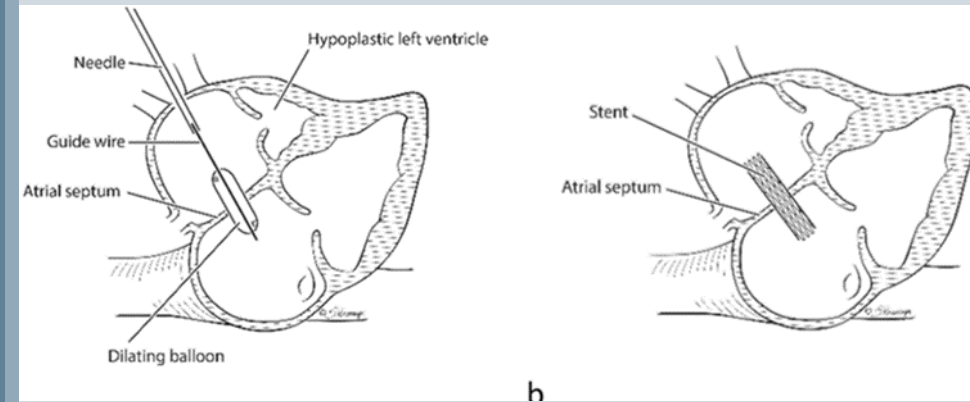
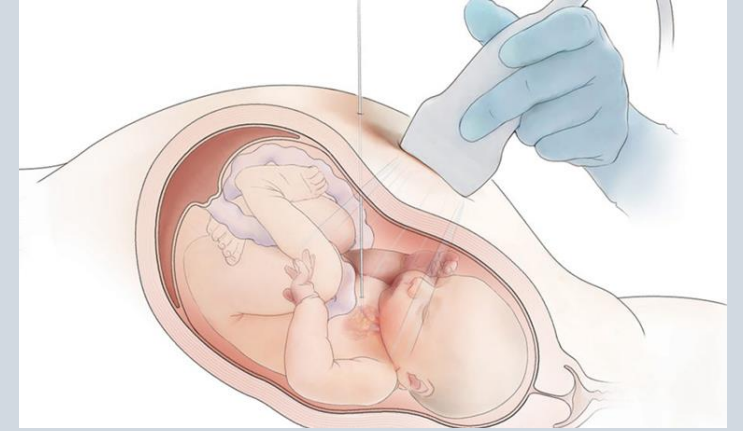- Other major fetal anomaly
- Major uterine anomaly
- Cerclage
- Maternal coagulopathy
- Maternal HIV+, Hep-B +, Hep-C+
- Hypertension not well controlled
- Contraindication to surgery/anesthesia
- Did not clear psychosocial evaluation
- Significant maternal comorbidities

Underwent initial atrial septal stent placement

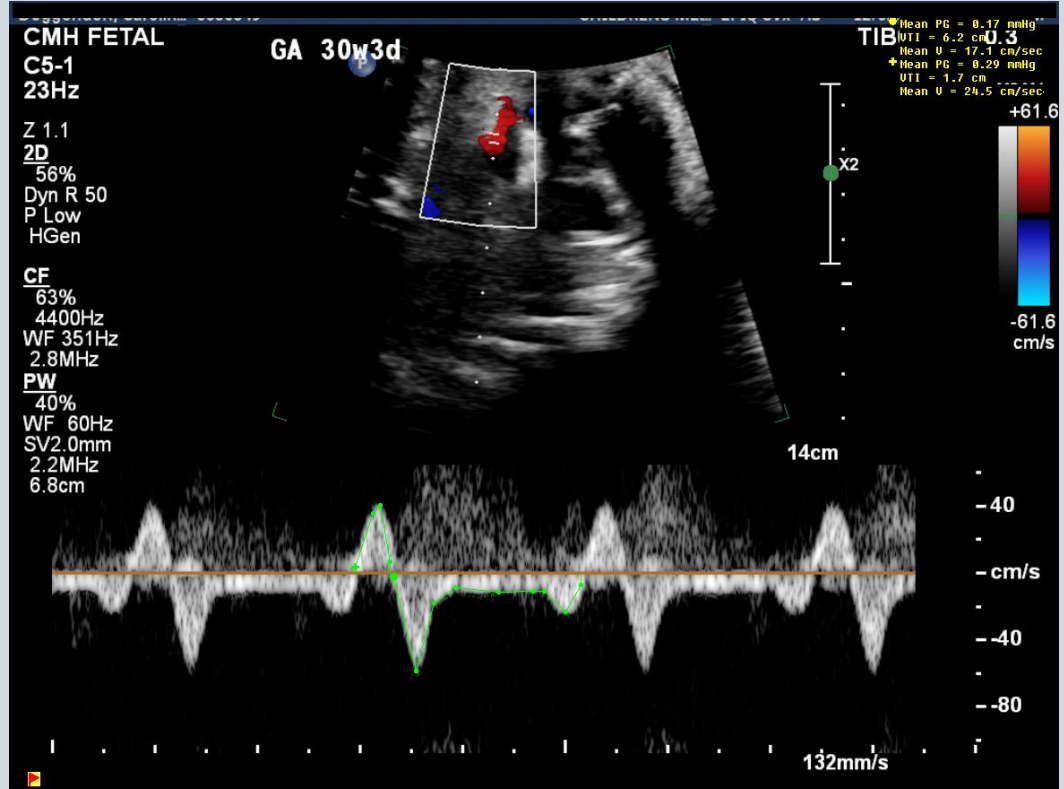
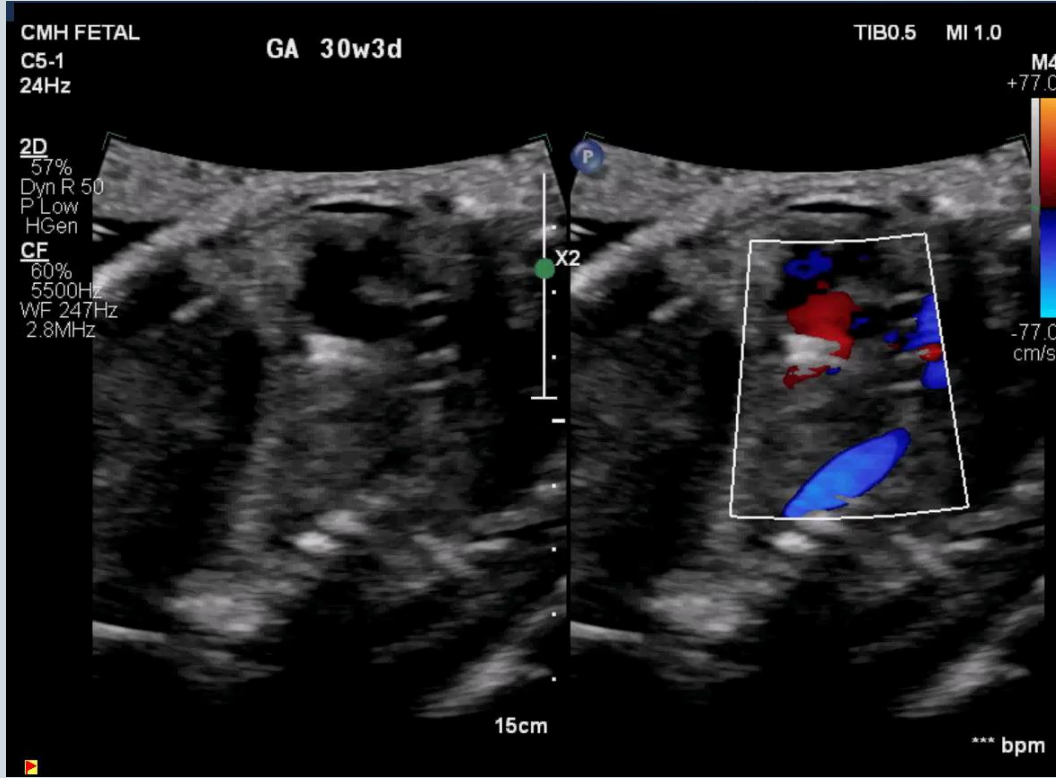
- The initial stent was successful; however, the following day was noted to have no flow thru stent with a pulmonary vein VTI ratio of about 2.

An additional atrial septal stent was placed 7 days later

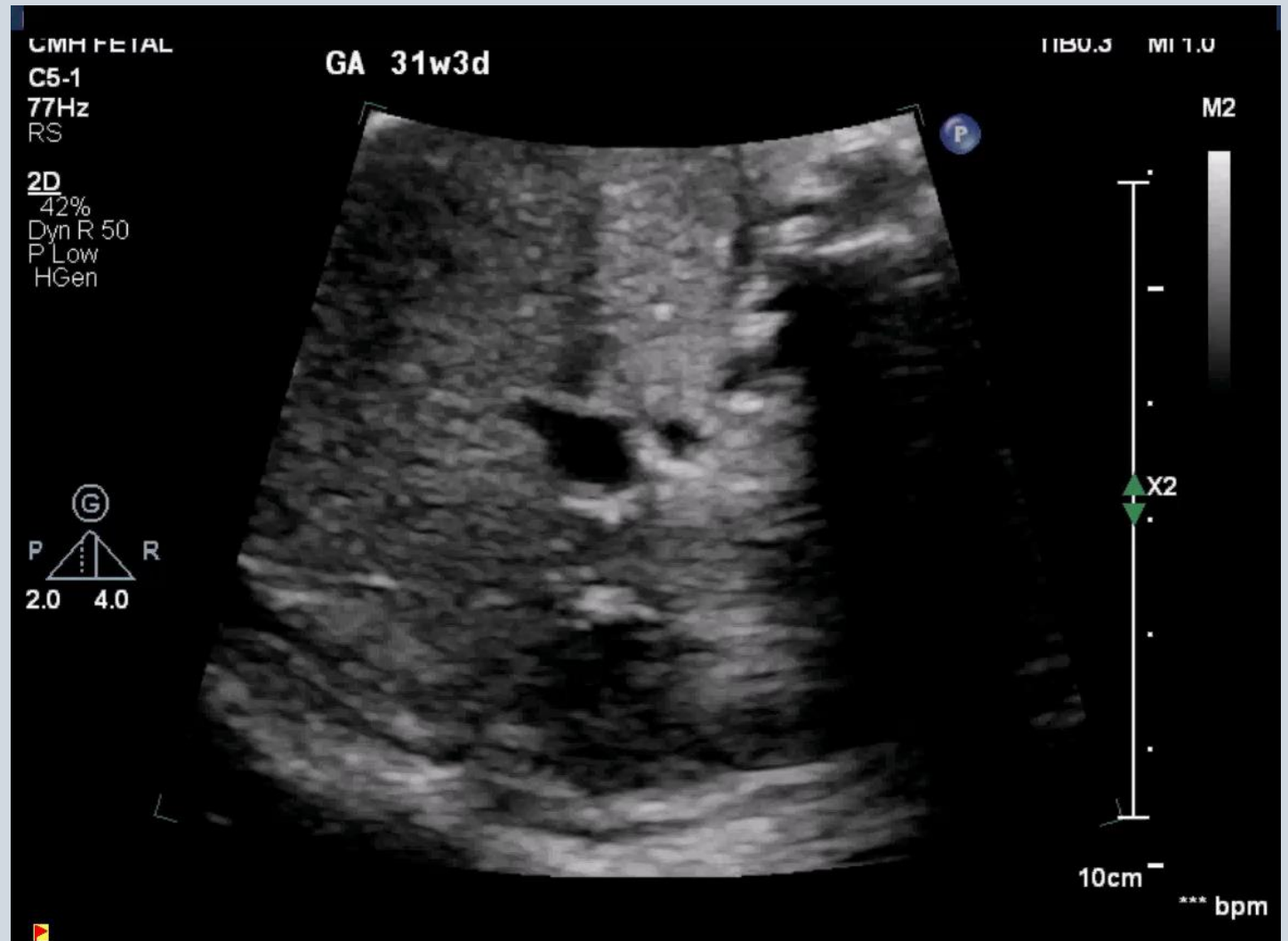- During second procedure, the fetus developed a large pericardial effusion and bradycardia requiring resuscitation. A right sided pleural effusion also developed with no intervention under the expectation this would most likely self-resolve.



# S/p Stent



- VTI improved
- Will likely have postnatal single ventricle physiology
- Single ventricle pathway





# Case #2- Comfort care

---

G4 P2

Singleton gestation at 20 weeks 4 days

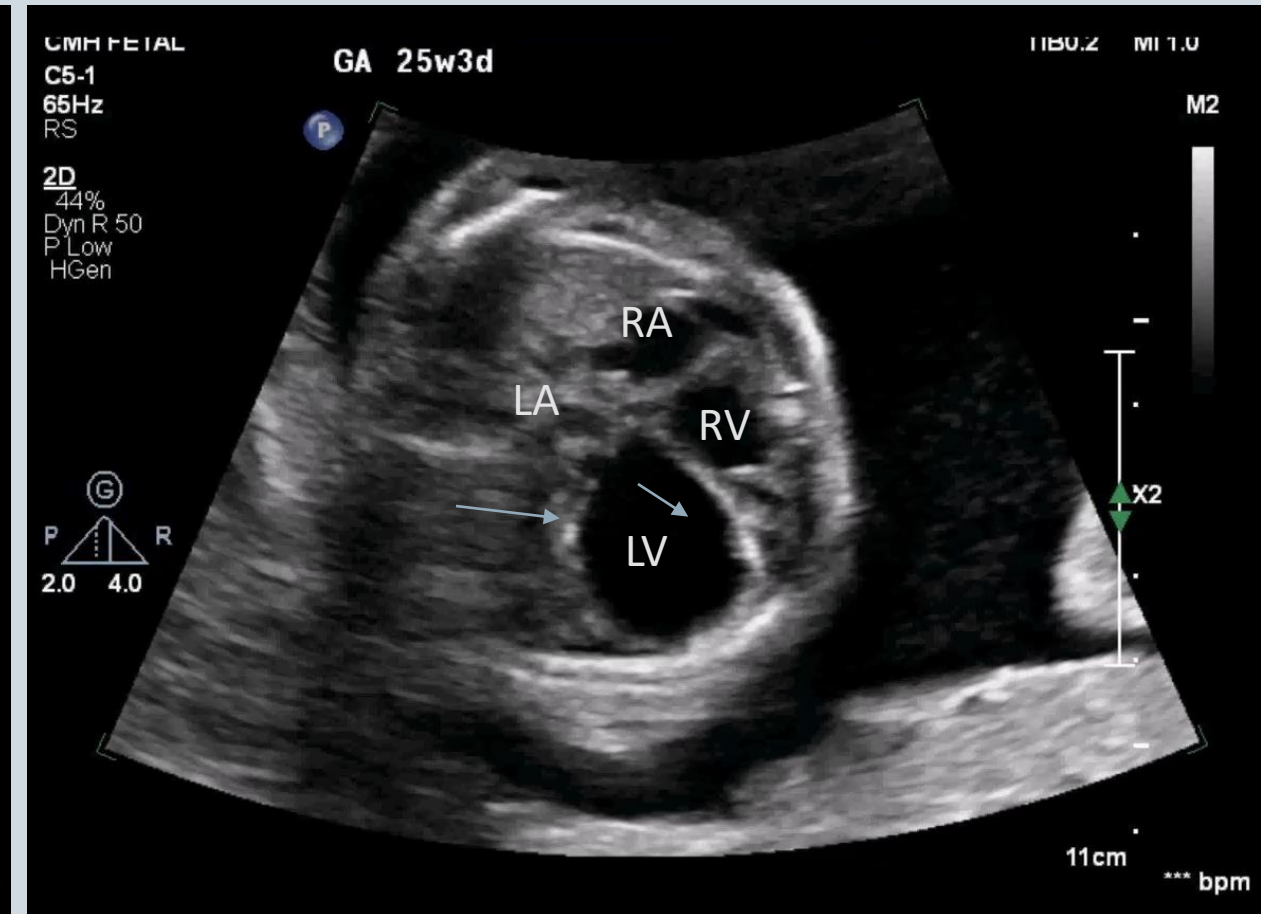
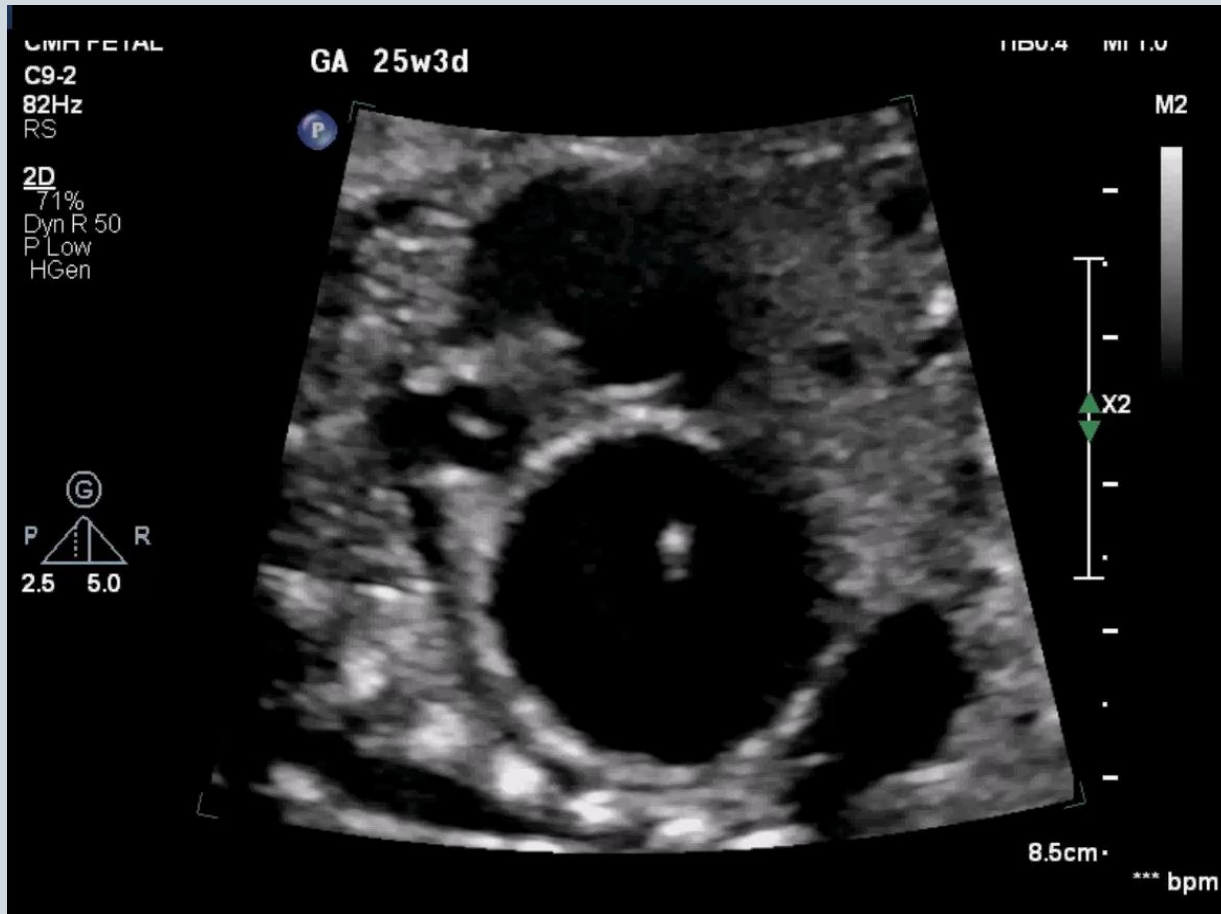Reason for study:

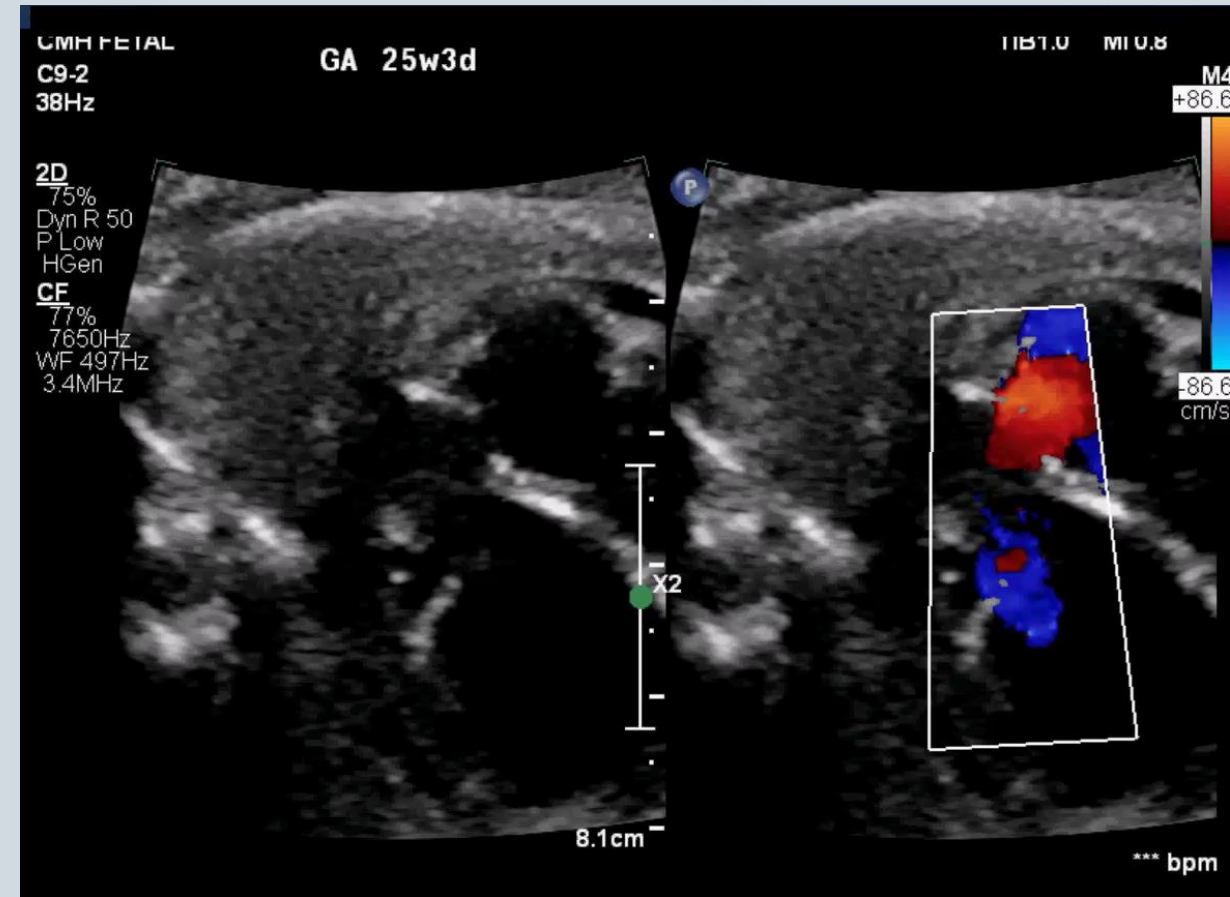
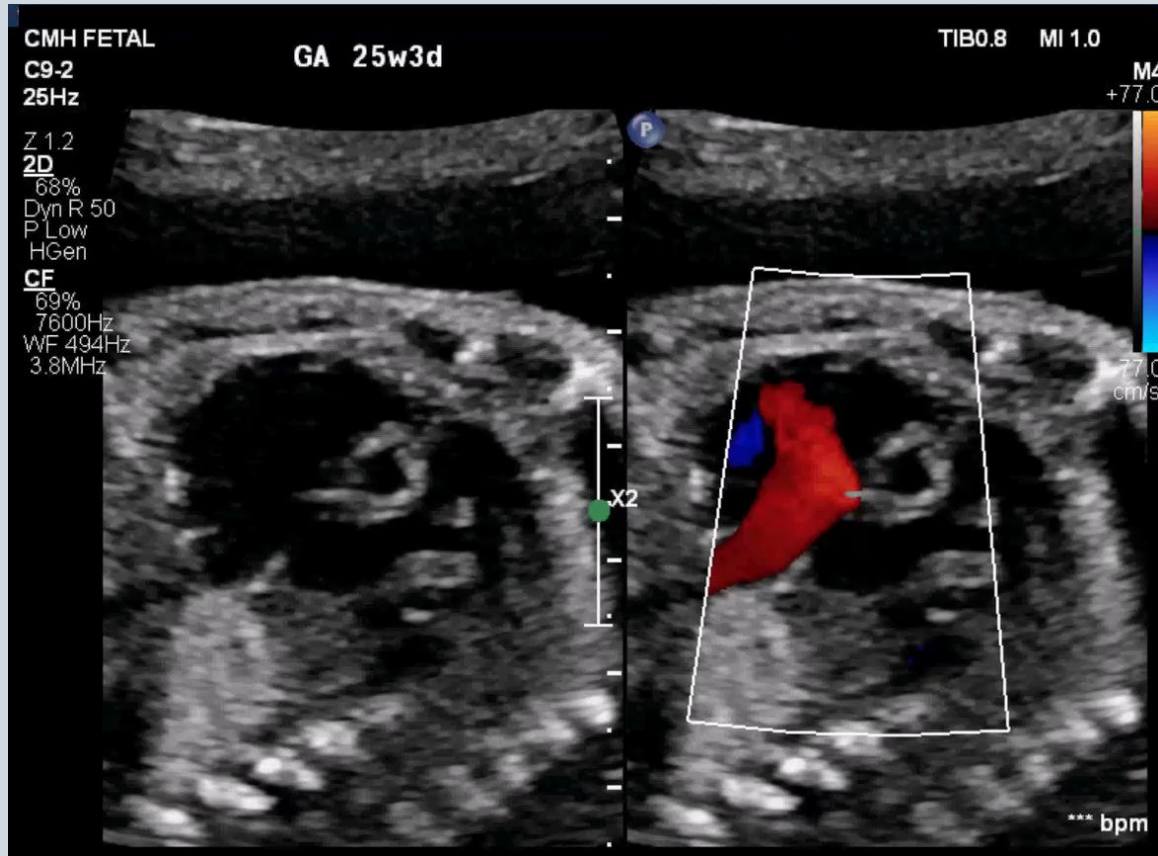
- Aortic stenosis

Diagnosis:

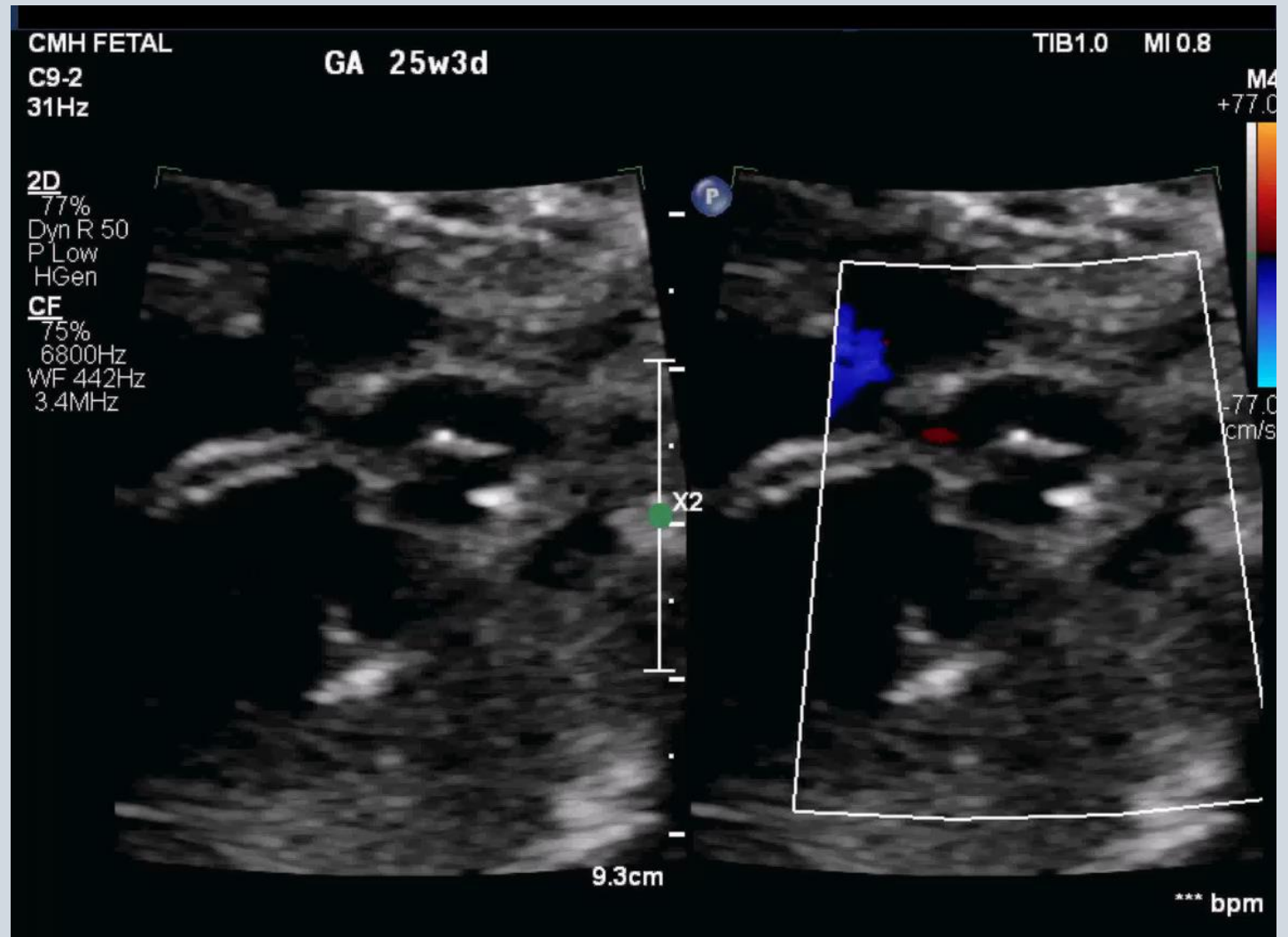
- Hypoplastic left heart syndrome variant (MS/AS)
- Normal mitral valve annulus size but with echo bright papillary muscles and chords suggestive of EFE
- Serial echoes to monitor progression

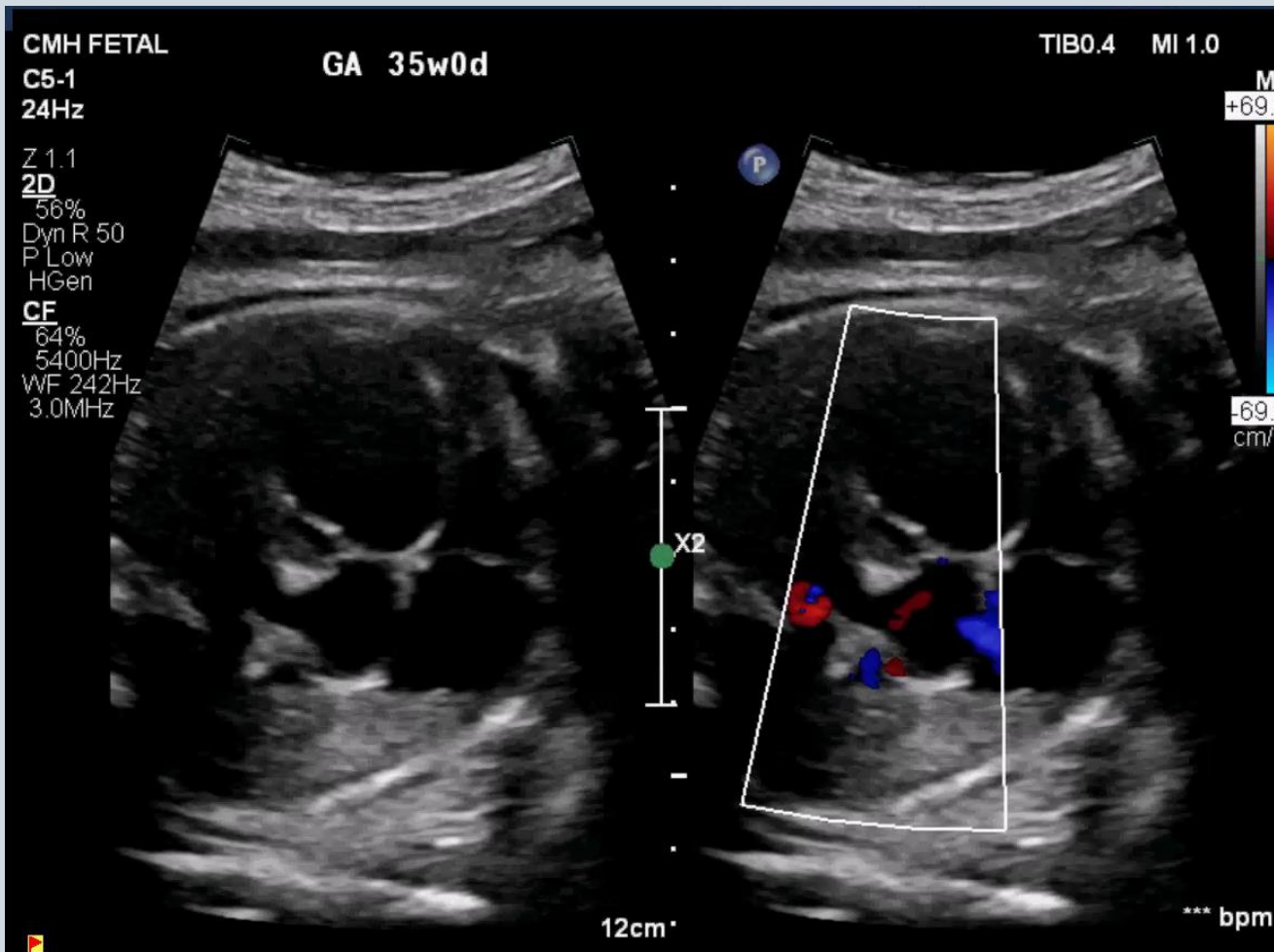
# 25 weeks 3 days





- Hypoplastic transverse arch with retrograde filling
- No antegrade flow thru the aortic arch determined fetus was not a candidate for fetal intervention



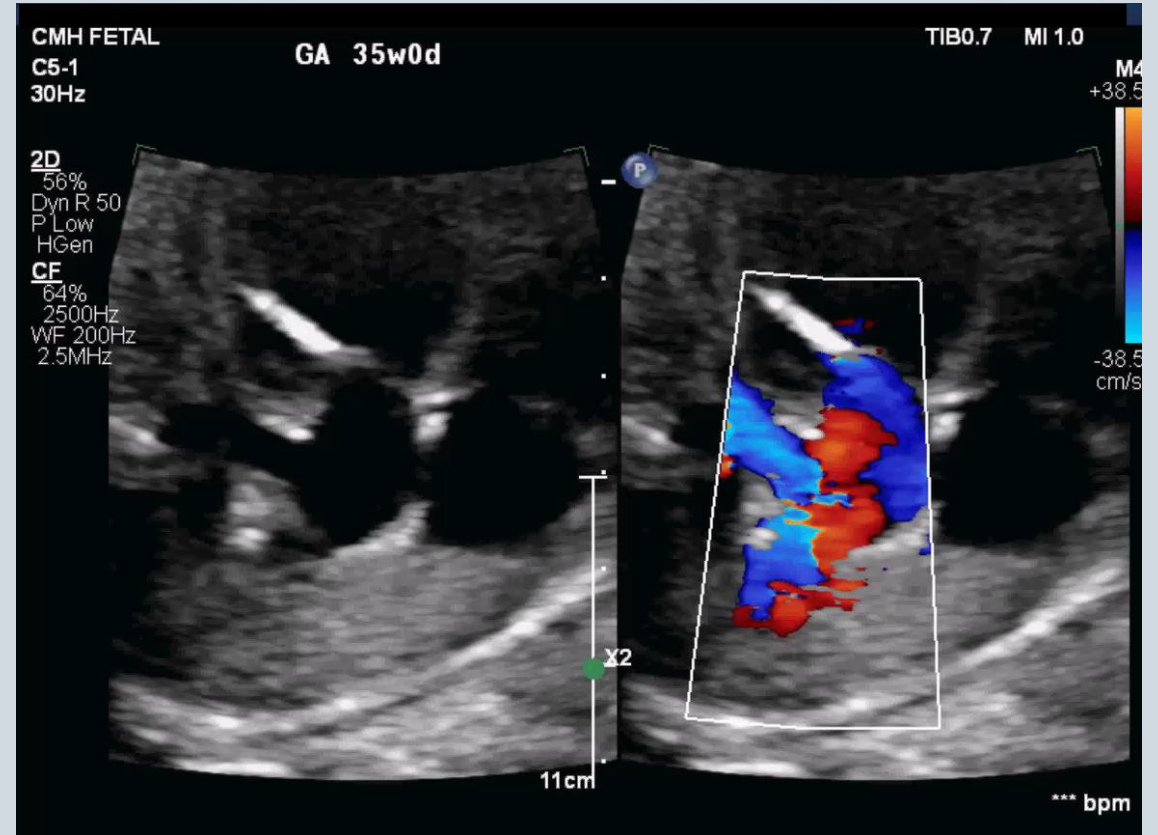
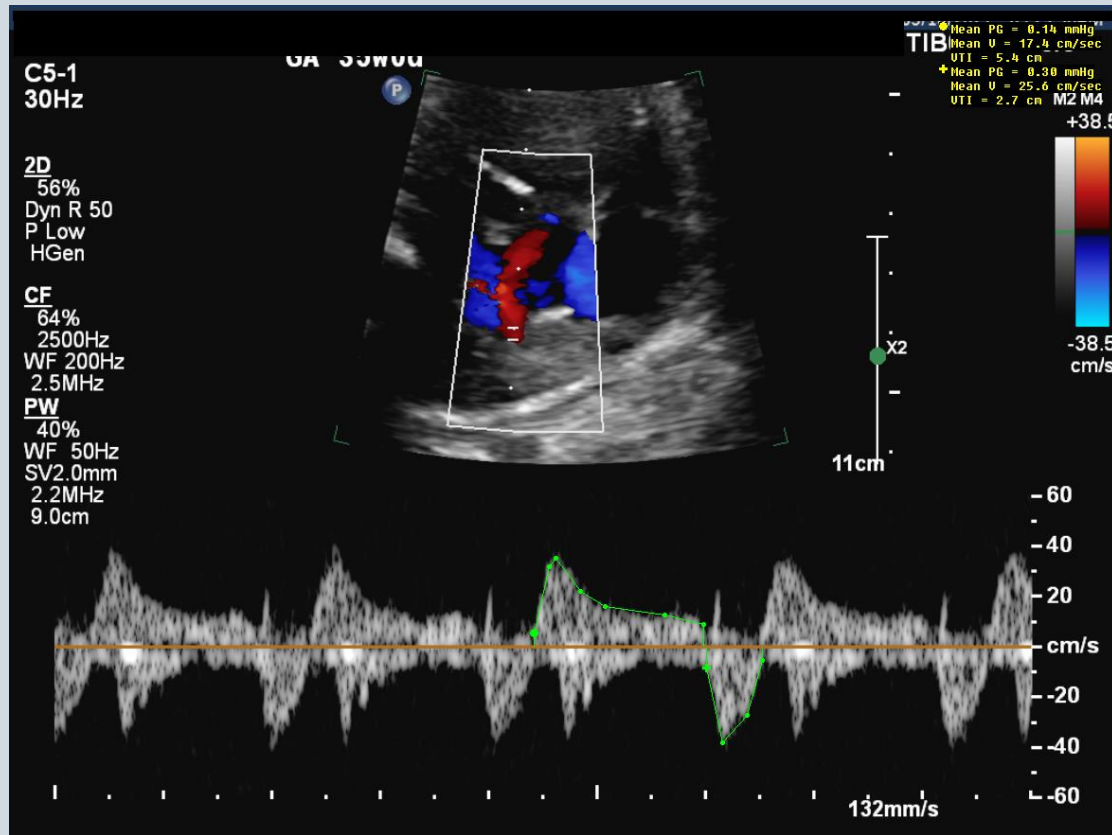


35 weeks



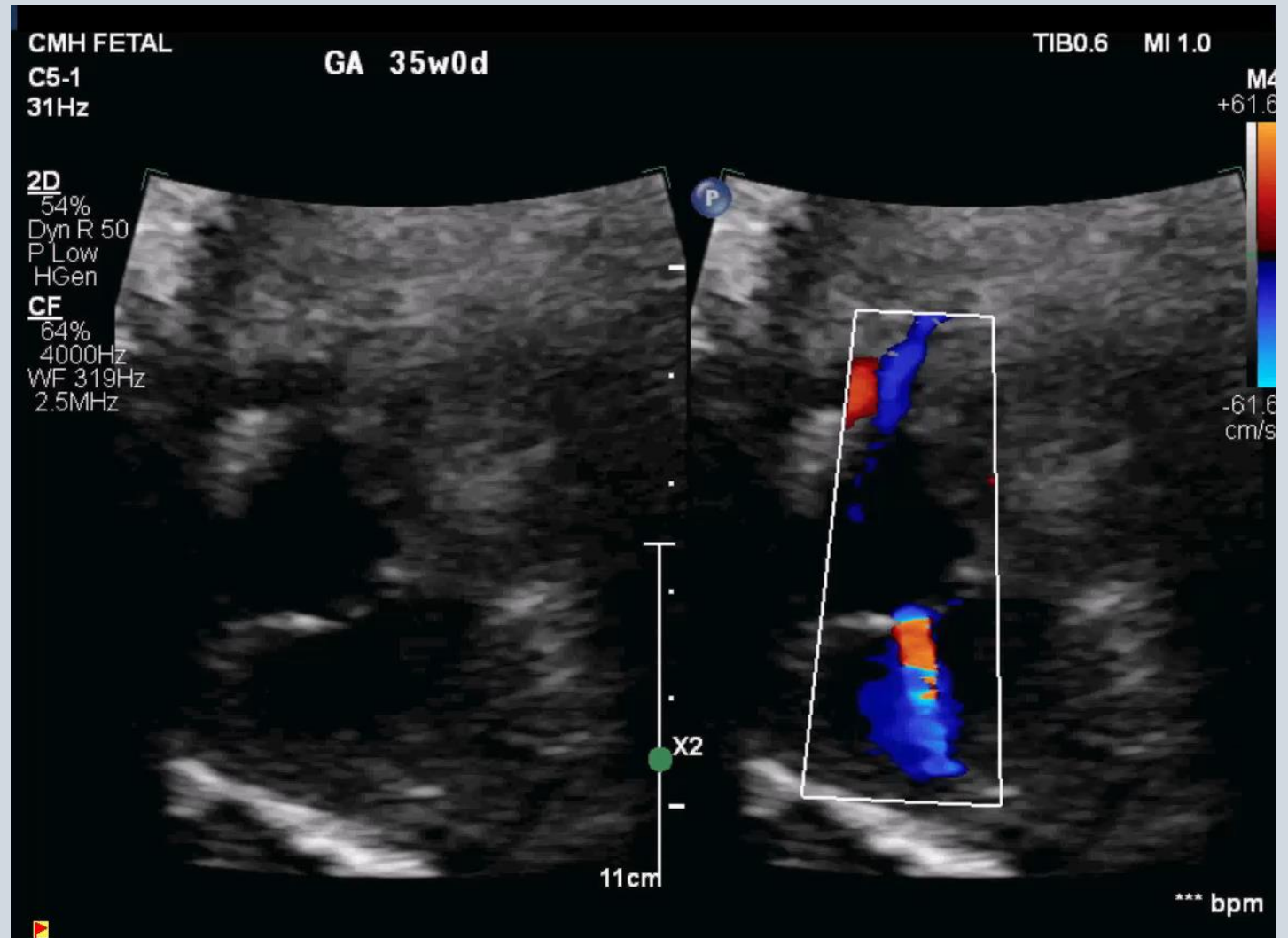
# Pulmonary veins

## VTI 3-4



# Atrial septum

- Left to right flow
- Increased gradient (6-7 mmHg)

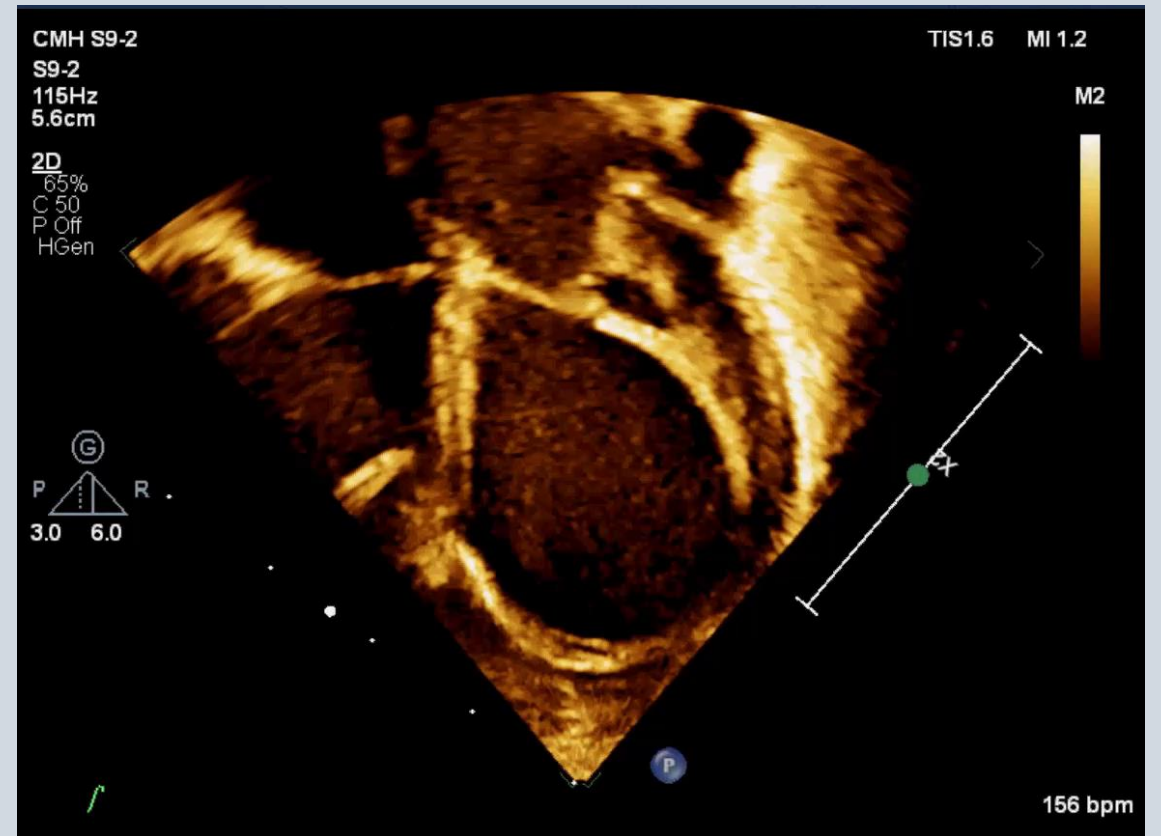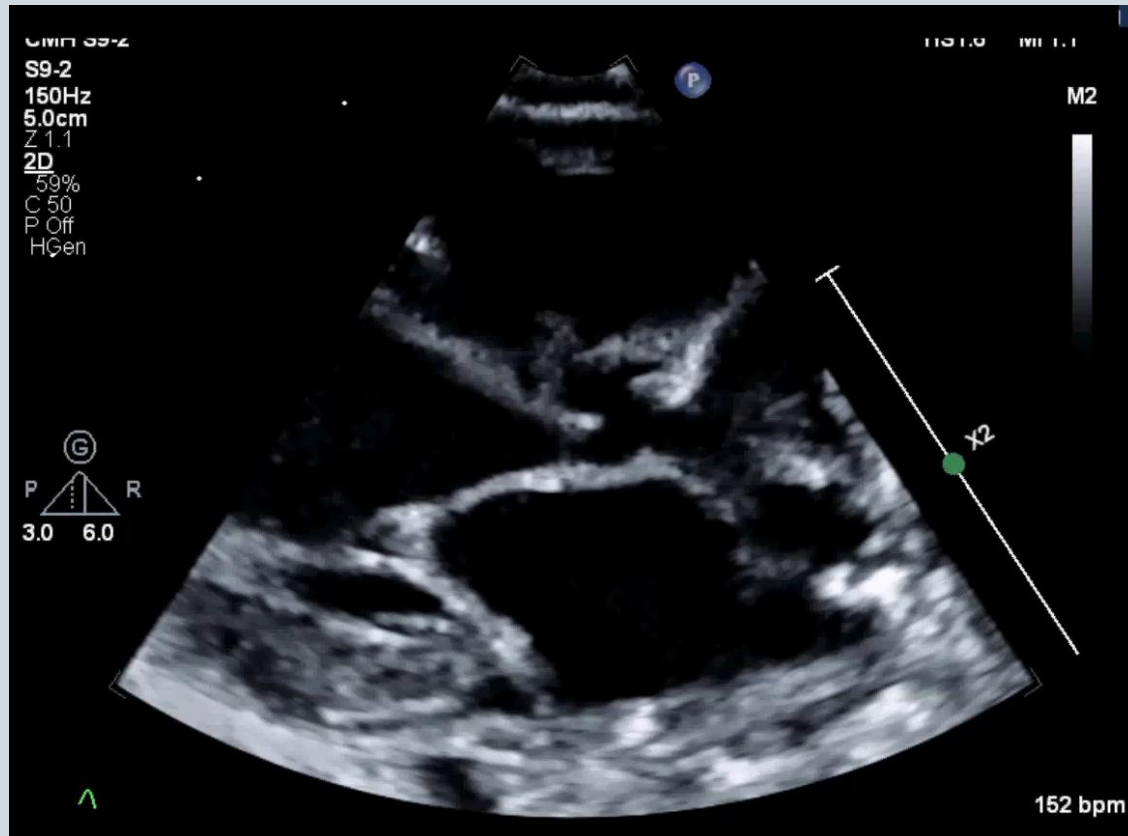


# Counseling

- Family discussion of hypoplastic left heart syndrome with restrictive atrial septum and likelihood of immediate intervention needed after birth with multiple surgeries to follow
- Given post natal options family chose comfort care with the goals of holding and allowing siblings to meet baby soon after birth
- Plan for immediate post natal echo confirming diagnosis

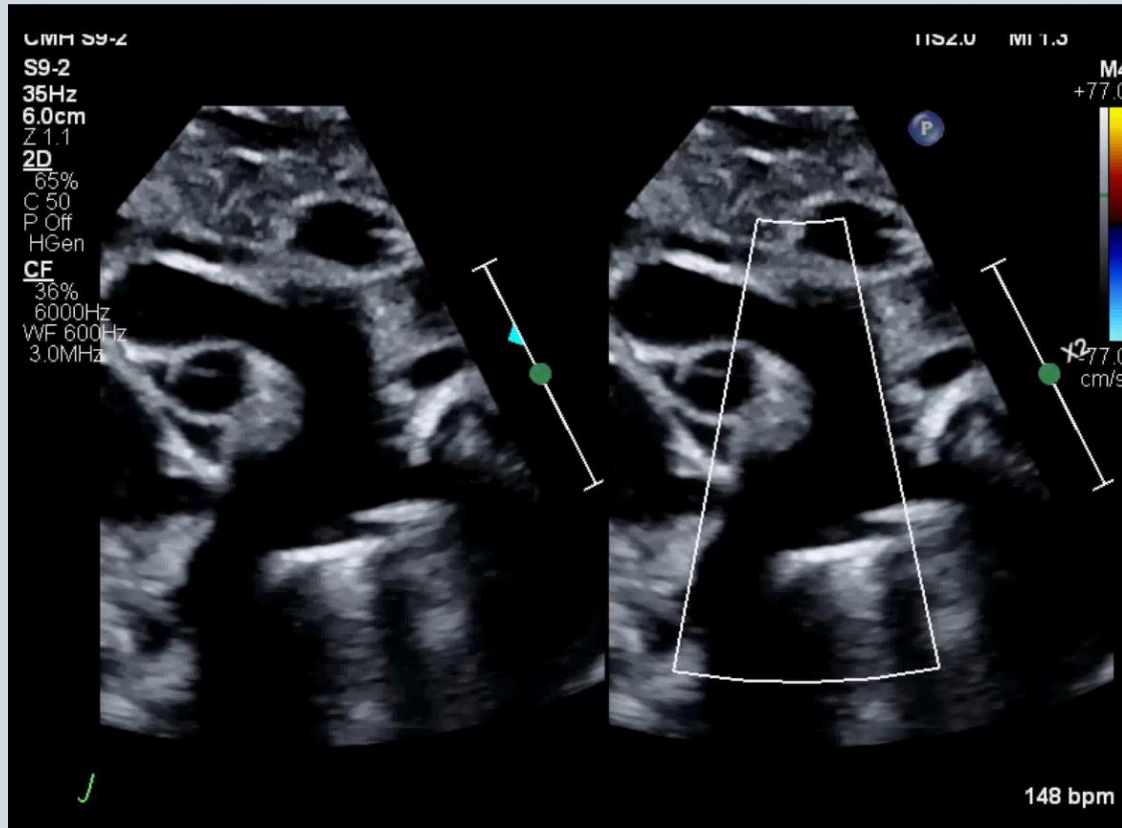


# Post natal echo

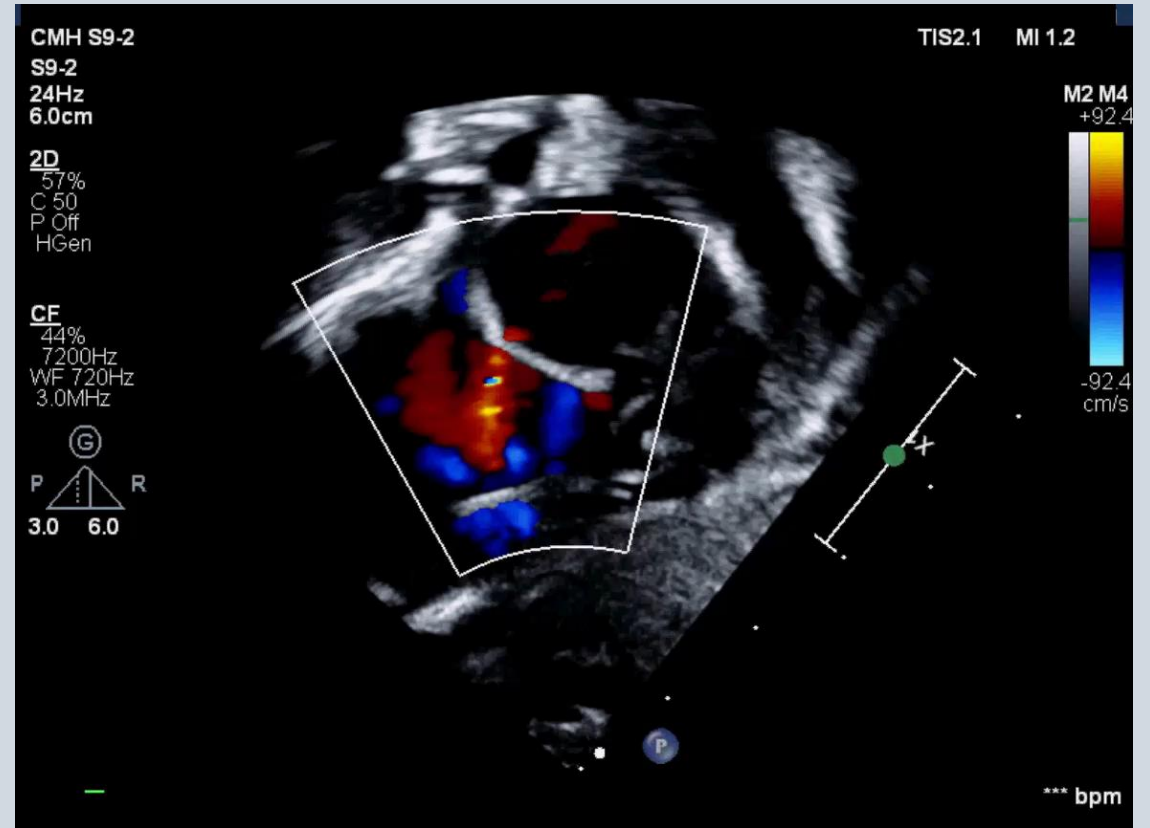


# Post natal echo

## RETROGRADE ARCH FILLING



## RESTRICTIVE IAS




# What is comfort care?

---

- Once a diagnosis has been determined; parents are counseled on possible outcomes, including:
  - Surgical option
  - Nonsurgical option; palliative care/hospice
- Since prenatal diagnosis is obtained parents have time to discuss and process all information and determine what they feel is best for their baby
- Comfort care creates a pathway for families to focus on infant comfort, contact with family members and creating positive memories with their newborn in the time they have together

# How we help families navigate

- Create goals
  - Do they want to hold immediately?
  - Sibling involvement
- Meet with palliative team
- Counseling
- Memory makers-handprints, photography, heartbeat bear

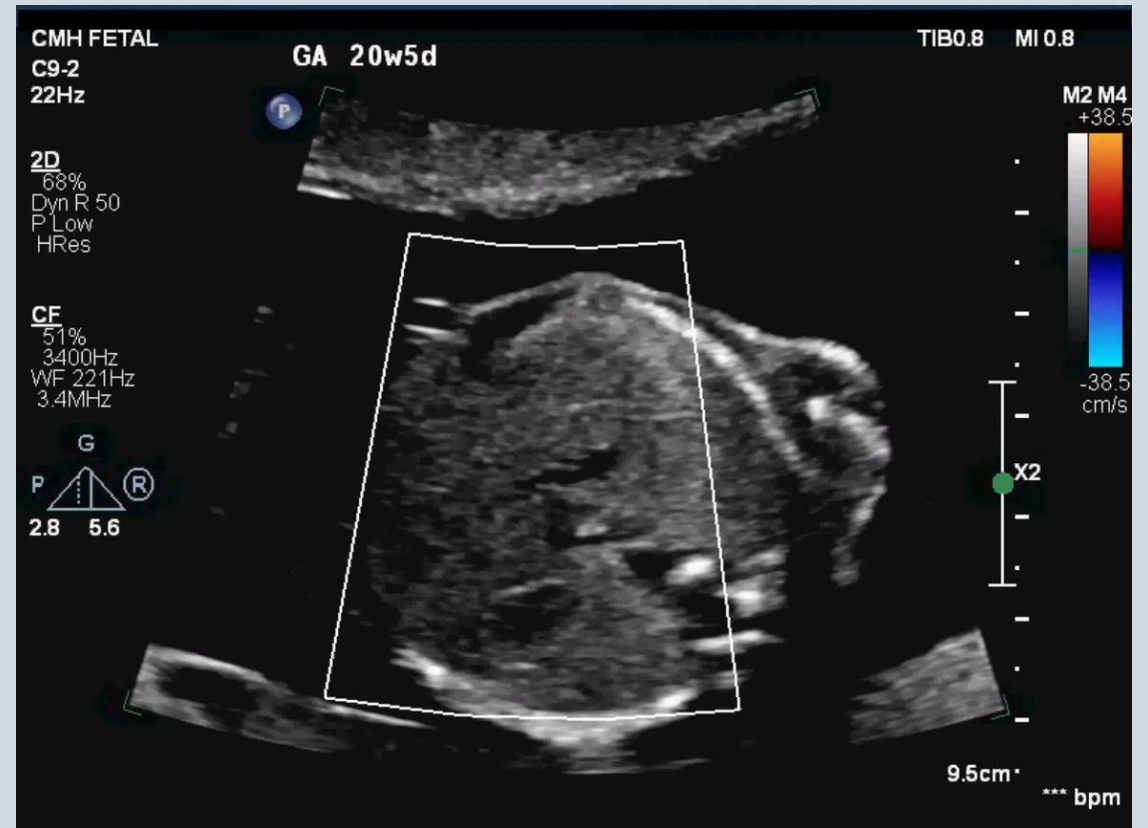
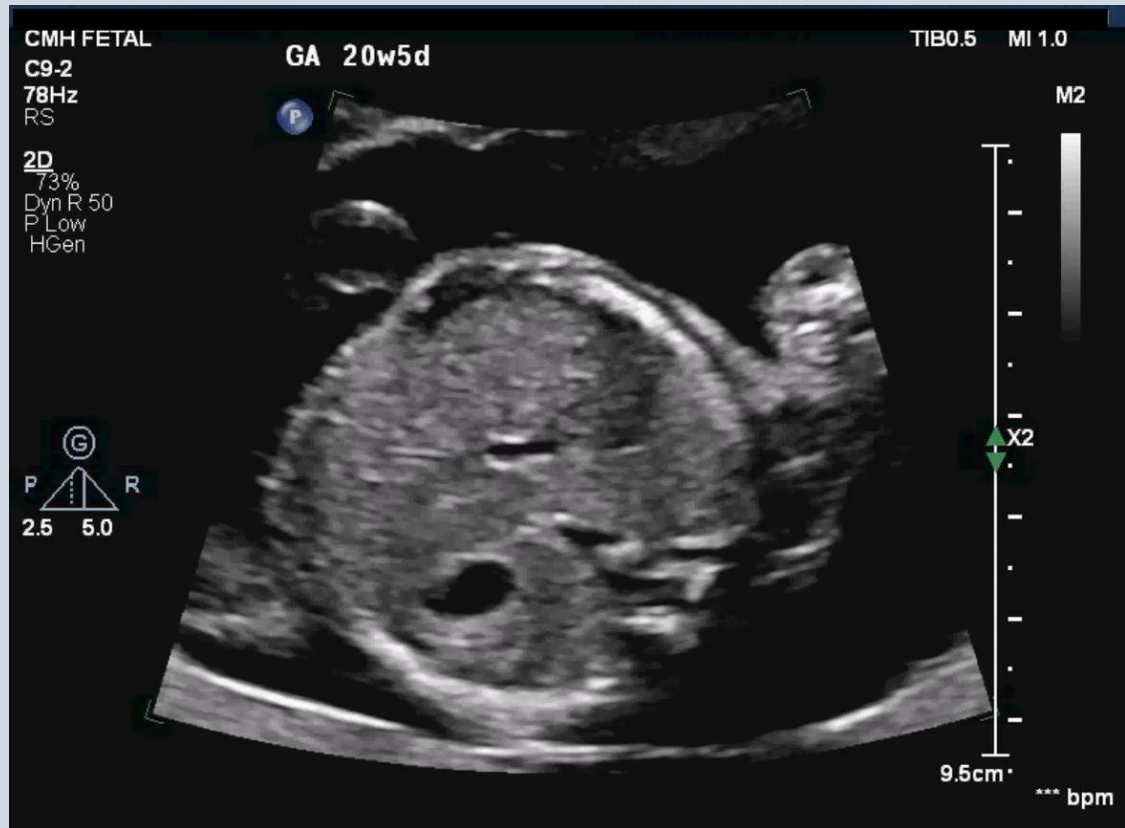
# Case #3- Hybrid

---

- G4 P2
- Singleton gestation at 20 and 5 weeks
- Reason for study:
  - Possible HLHS
- Diagnosis:
  - Moderate aortic valve stenosis
  - Mild mitral and tricuspid insufficiency
  - Borderline biventricular systolic function

# 20 weeks 5 days



# The plan...

---

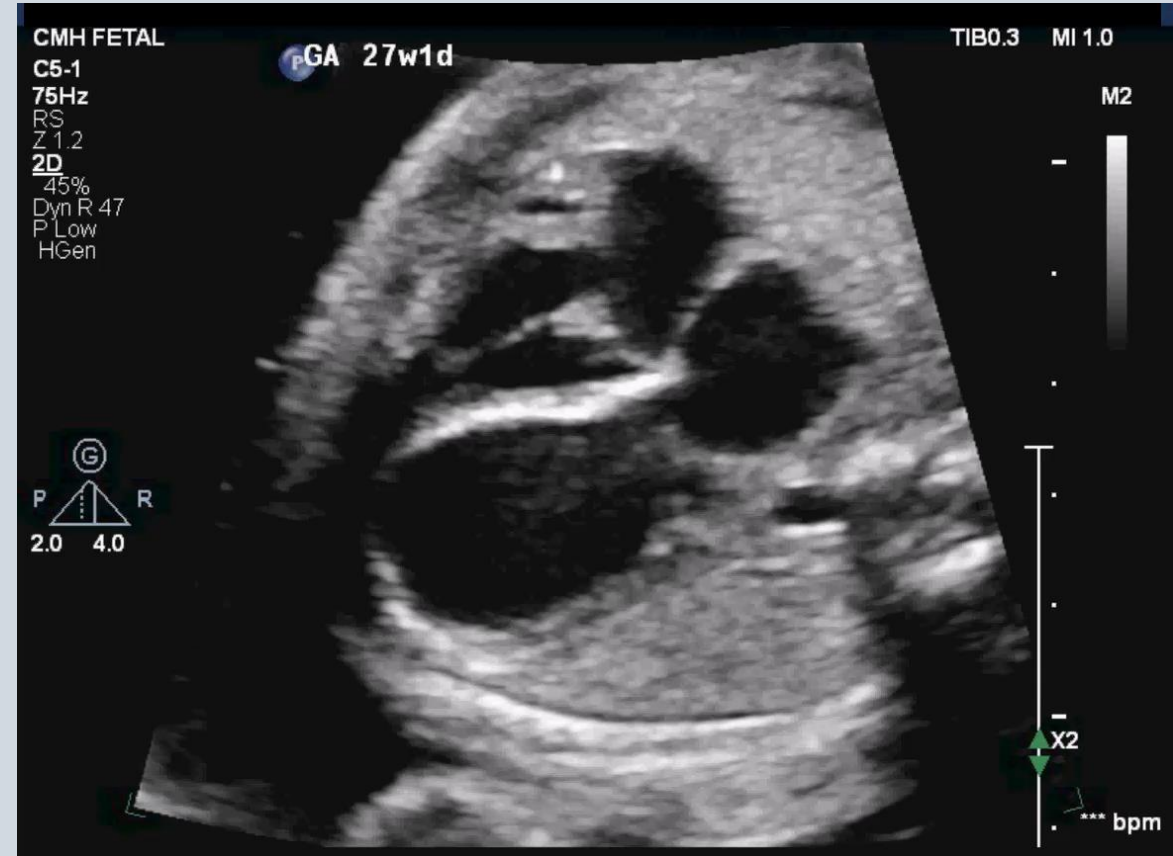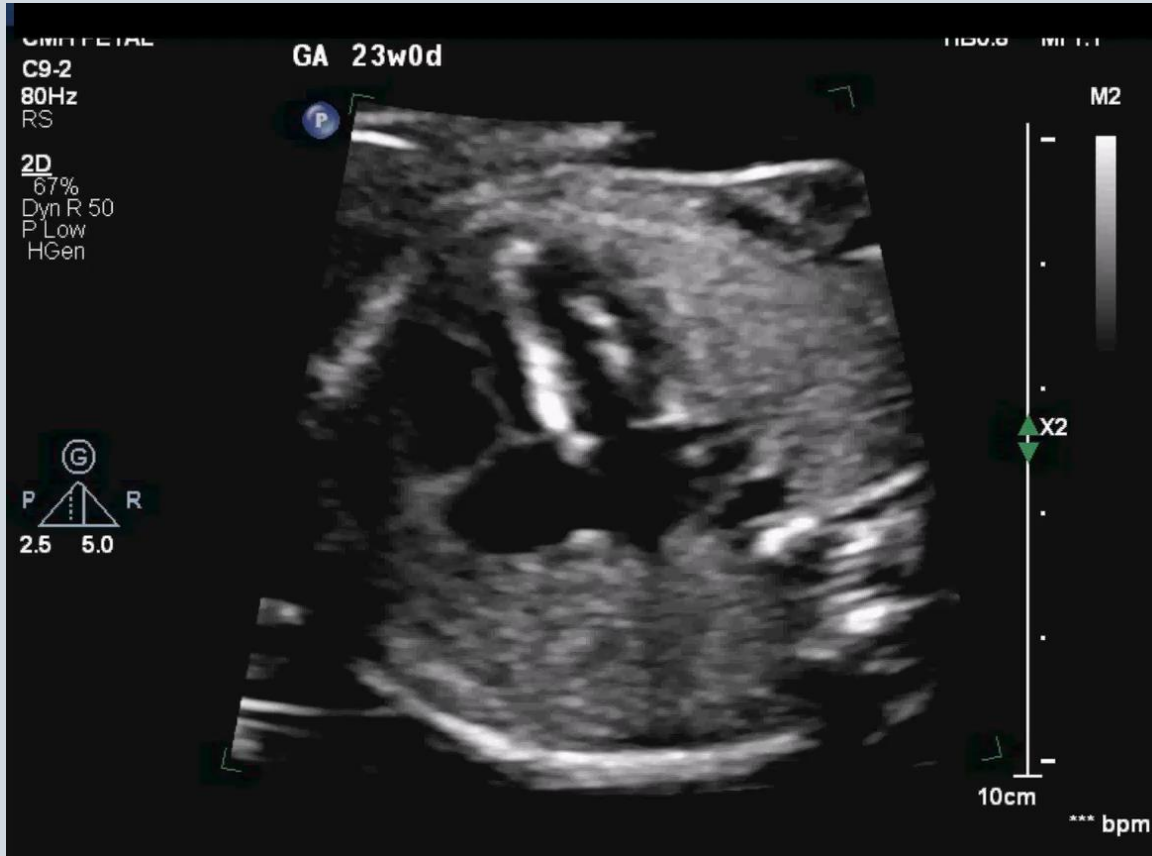- Family counseled on multiple scenarios
- A wait and see situation
- Echo performed 2 weeks after initial study with little to no changes
- Serial echoes planned



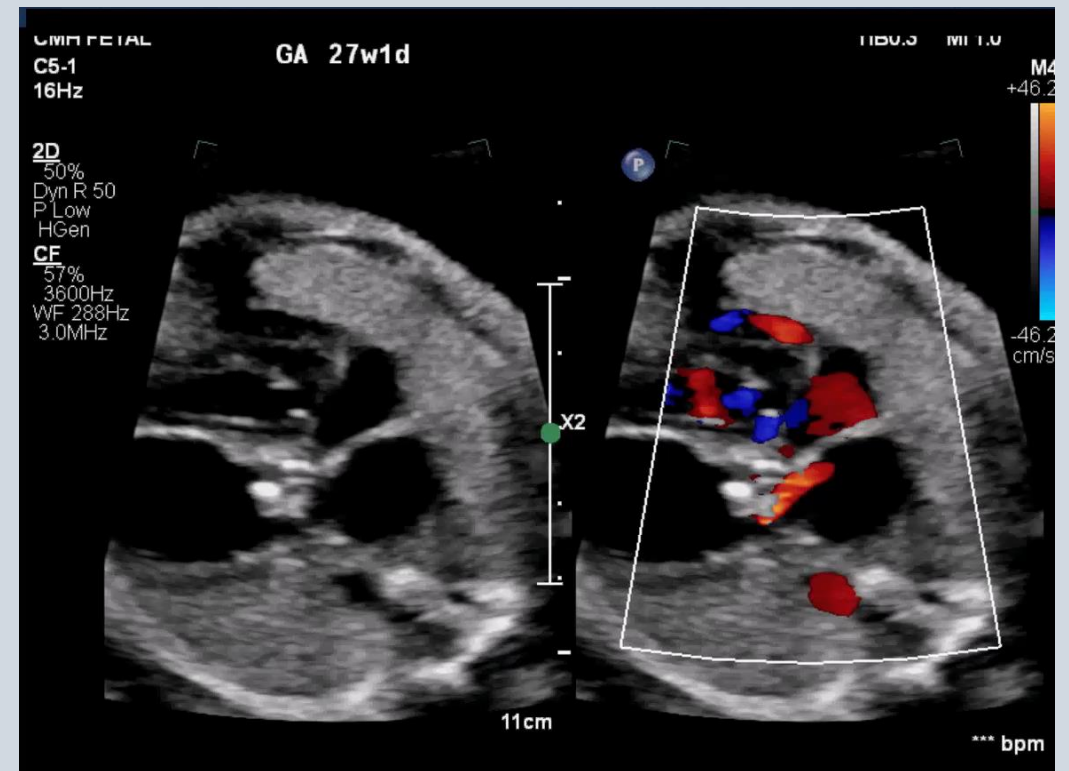
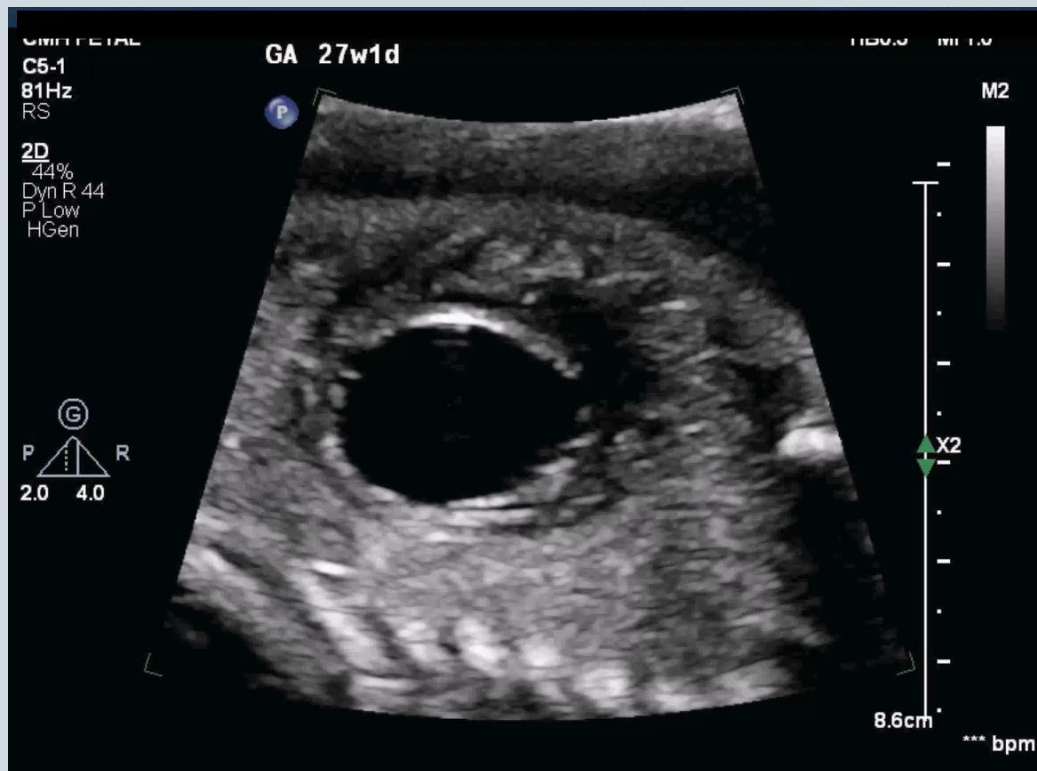# Serial echoes

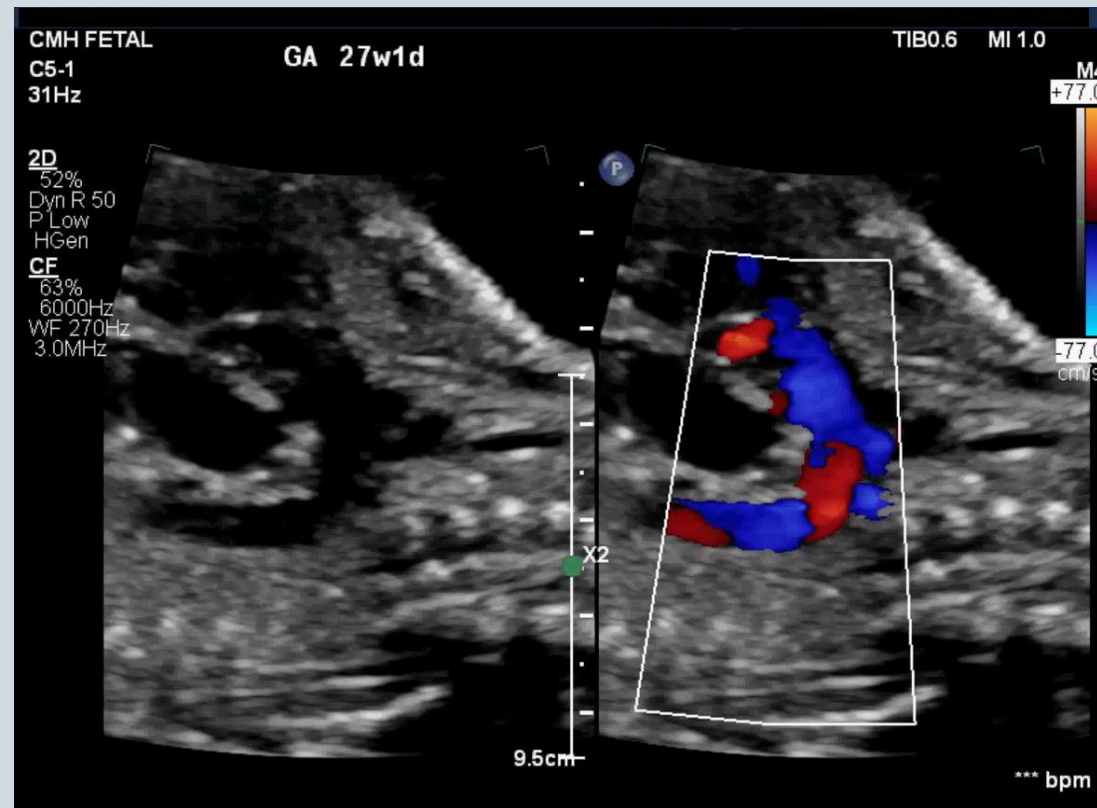
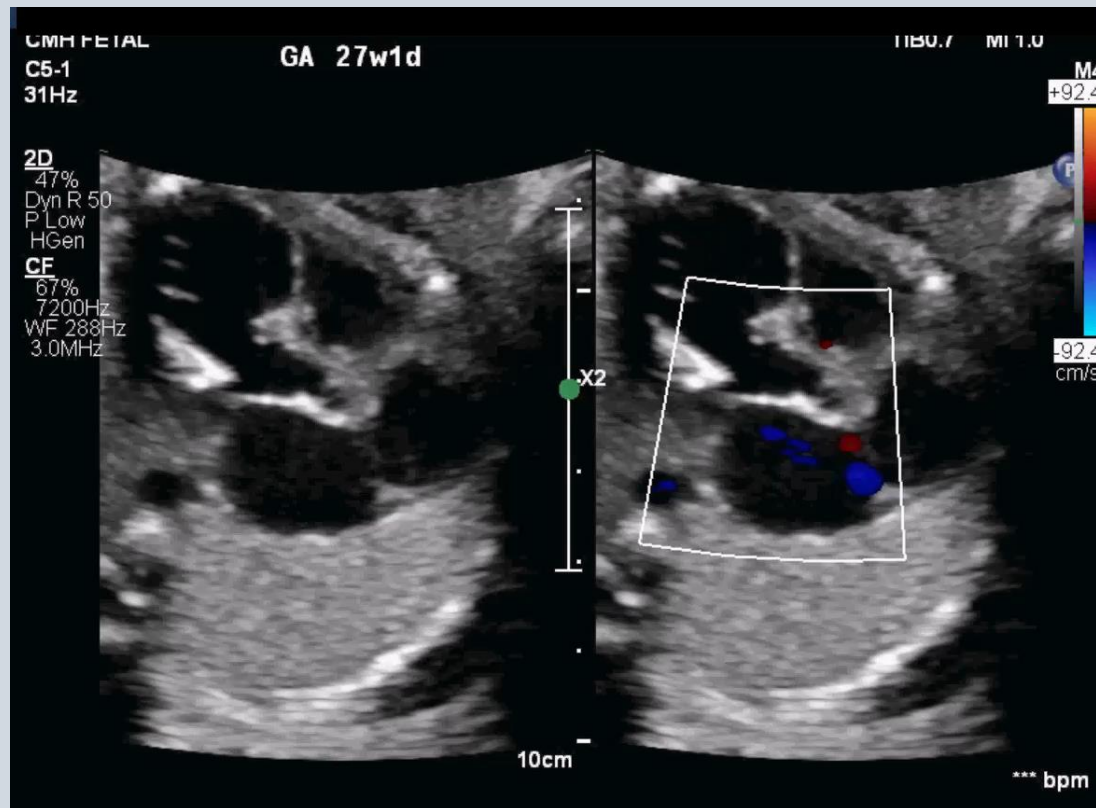
23 WEEKS (2 WEEKS AFTER INITIAL STUDY)

27 WEEKS 1DAY









CMH FETAL  
C5-1  
20Hz

GA 27w1d

TIB0.4 MI 1.0

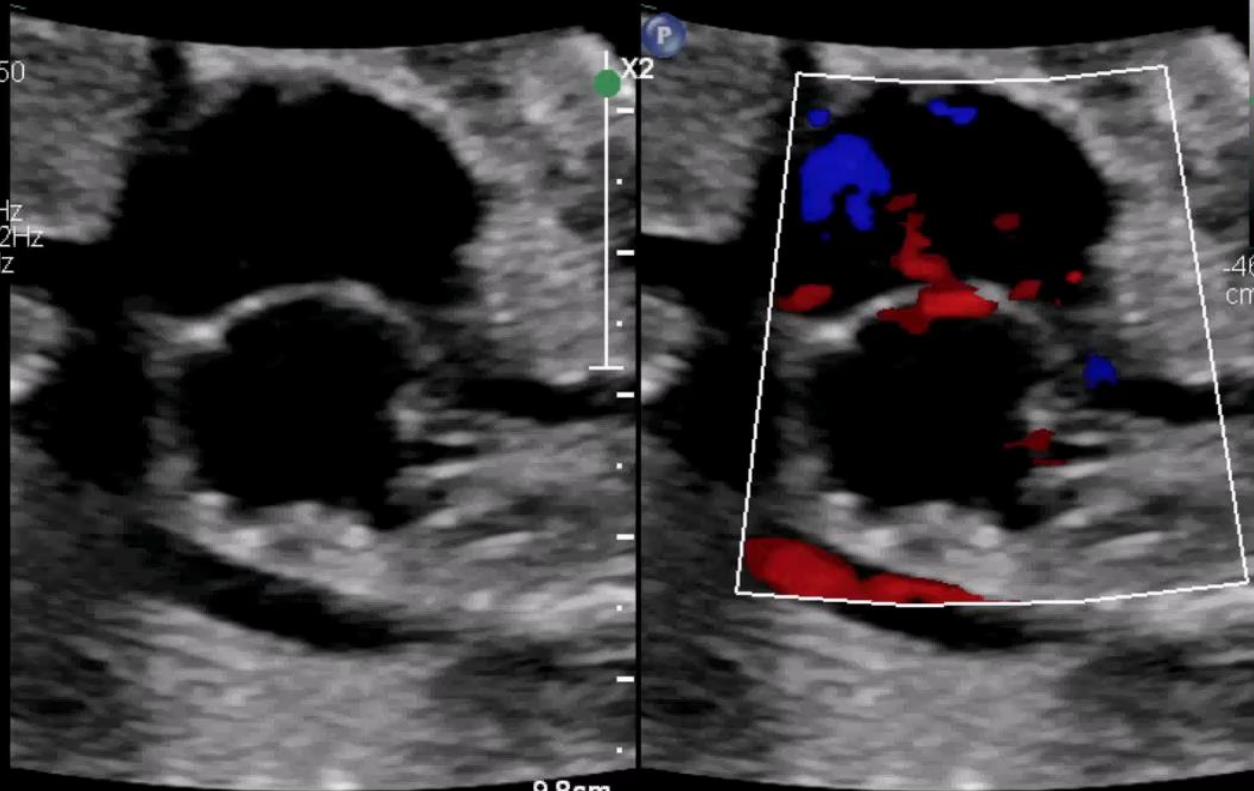
M4  
+46.2

**2D**

51%  
Dyn R 50  
P Low  
HGen

**CF**

63%  
3900Hz  
WF 312Hz  
3.3MHz



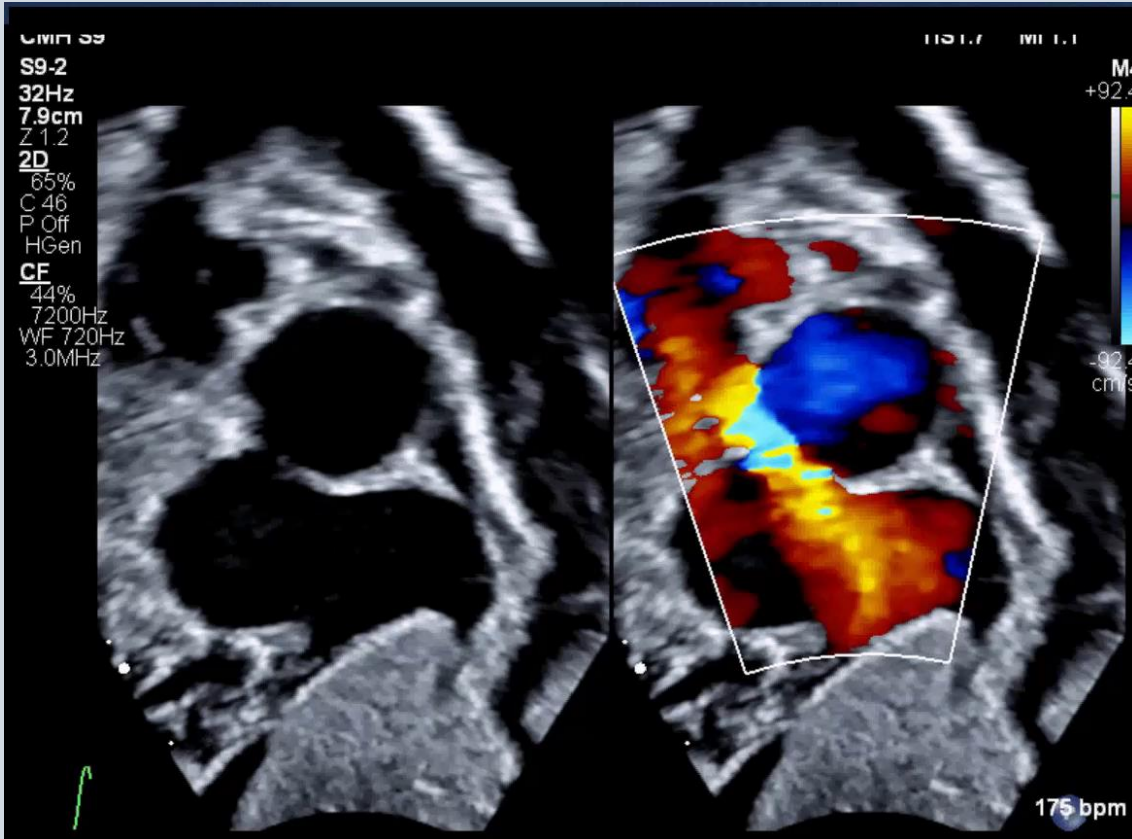
-46.2  
cm/s

9.8cm

\*\*\* bpm

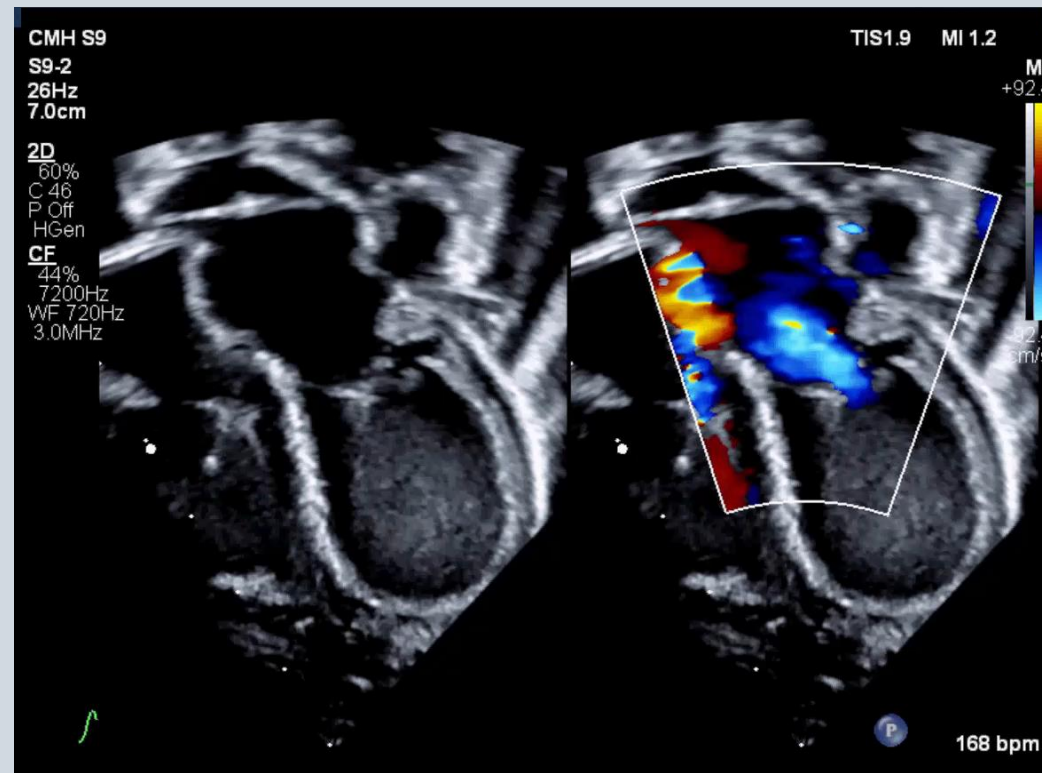
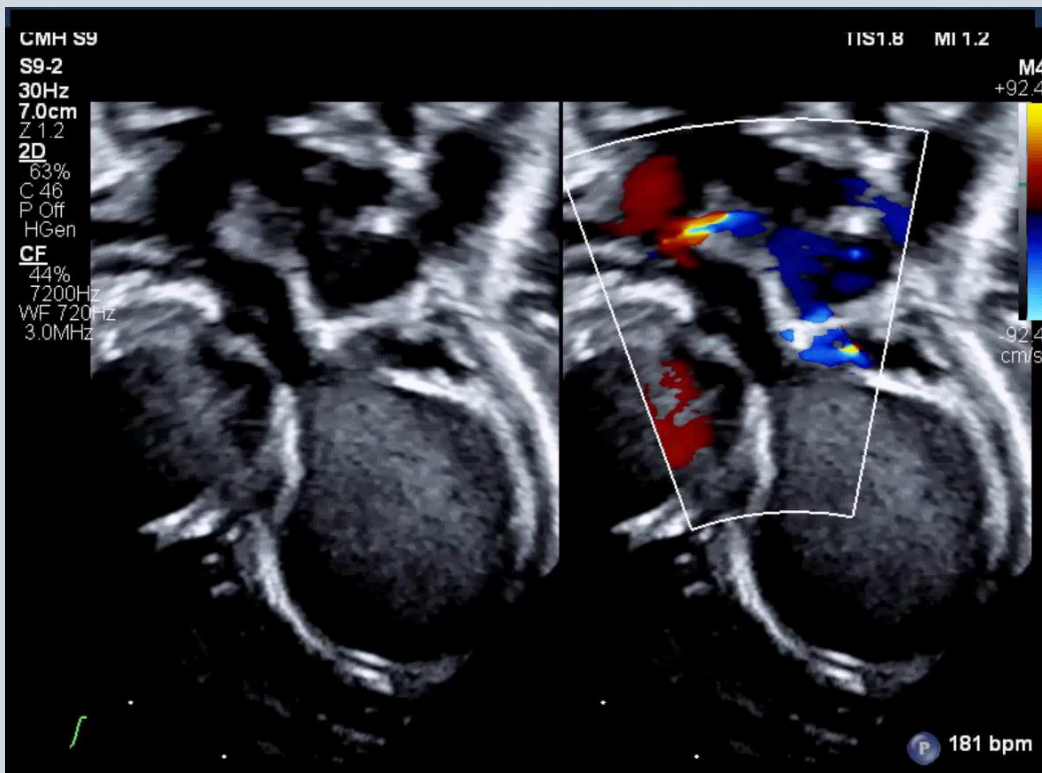
- 
- Fetus determined not a candidate for fetal intervention (balloon valvuloplasty) due to:
    - Left ventricular dilation and function
    - EFE-echo brightness of myocardium and mitral valve papillary muscles- recovery of LV function thought to be unlikely
  - Evolving hypoplastic left heart syndrome
    - Single ventricle palliation

# Postnatal echo

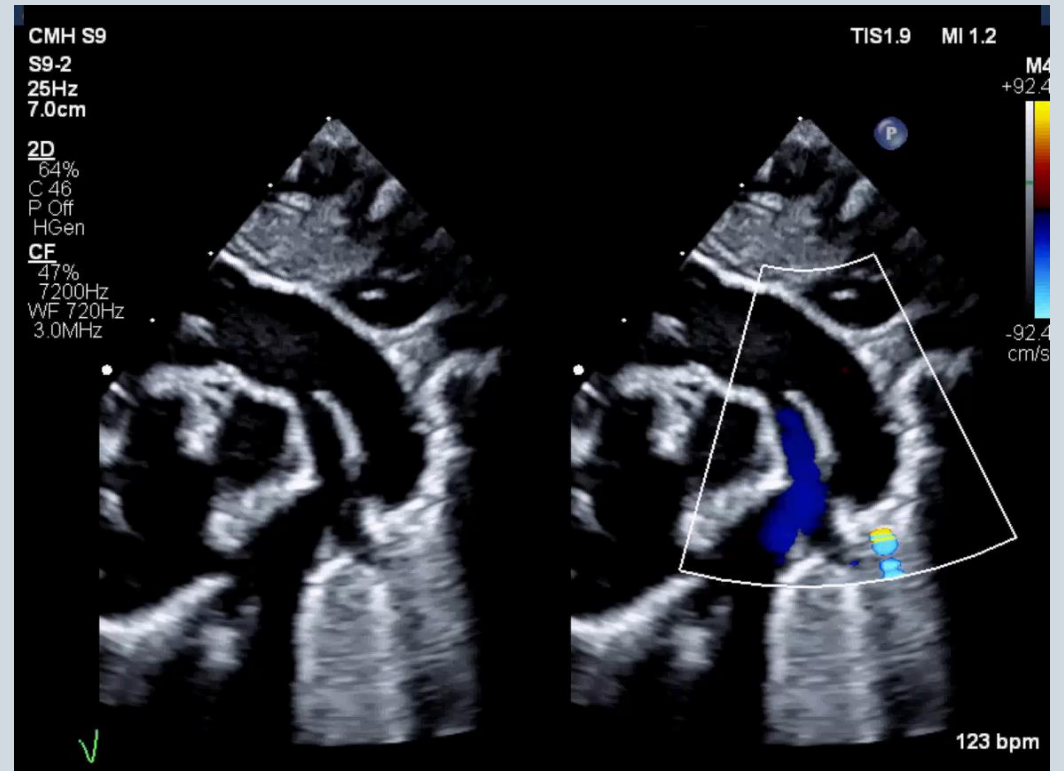
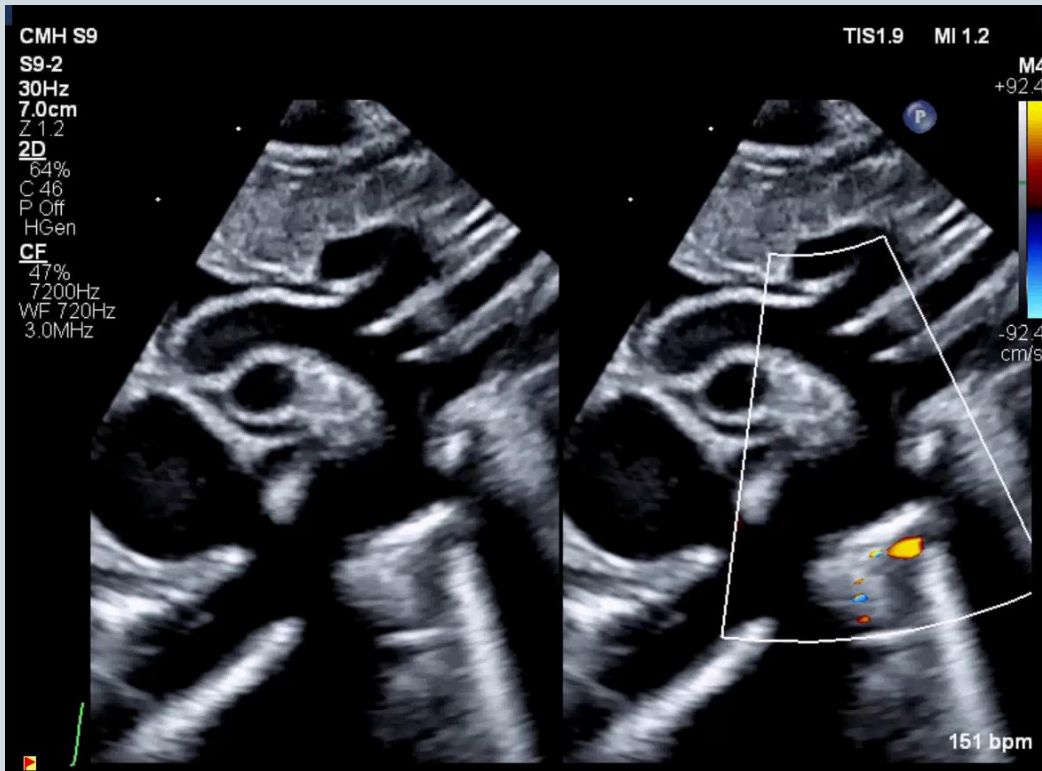


- Baby required prostaglandins immediately after birth to keep patent ductus arteriosus open
- Clinically was shown to have reasonable cardiac output so immediate intervention not needed
- Close monitoring of RV function will determine next steps to take:
  - Hybrid
  - Norwood/shunt



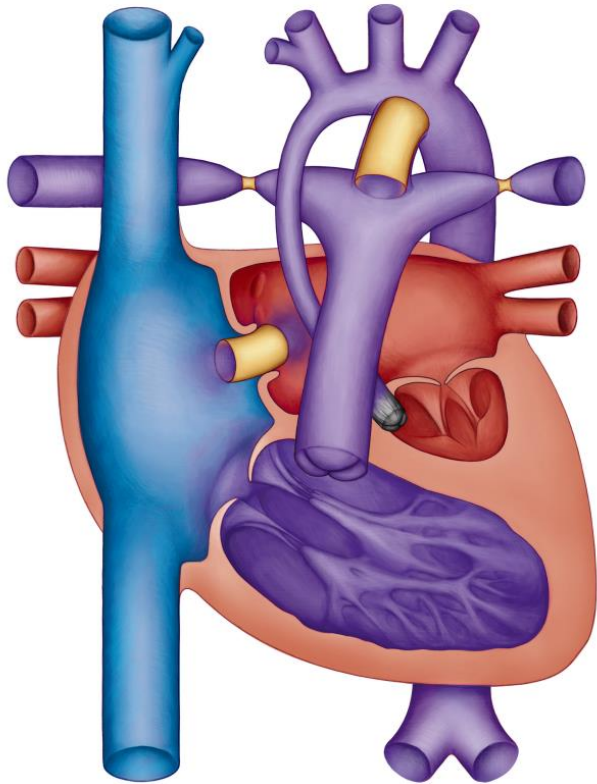




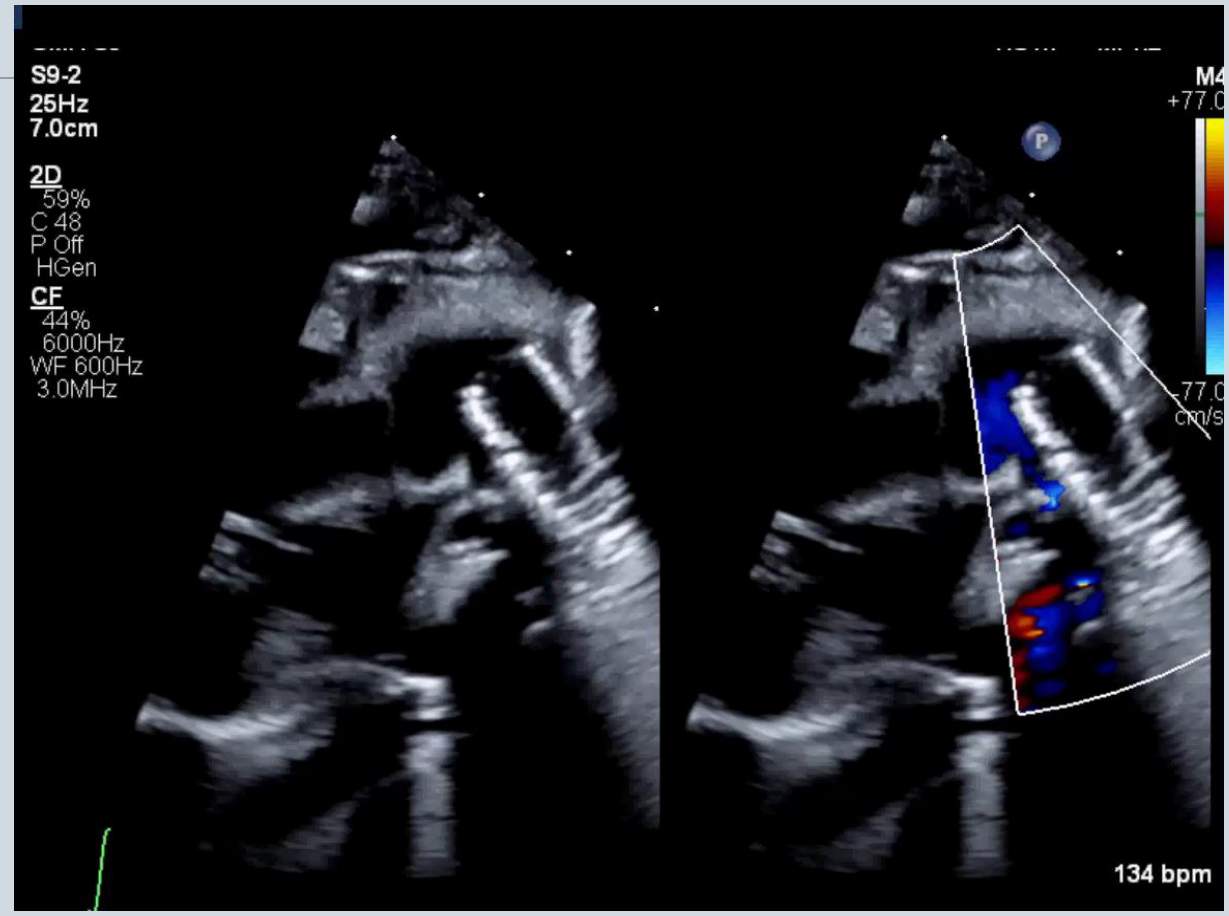
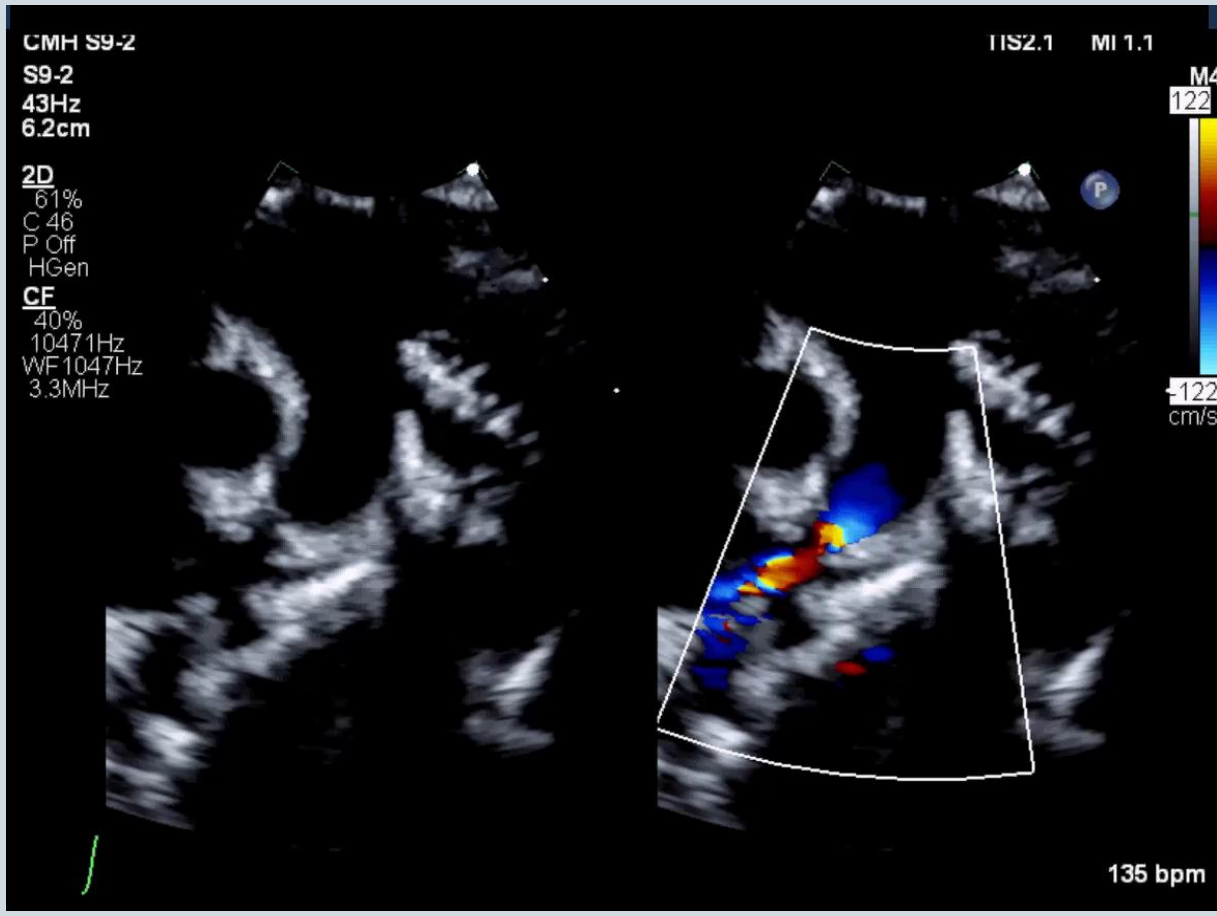


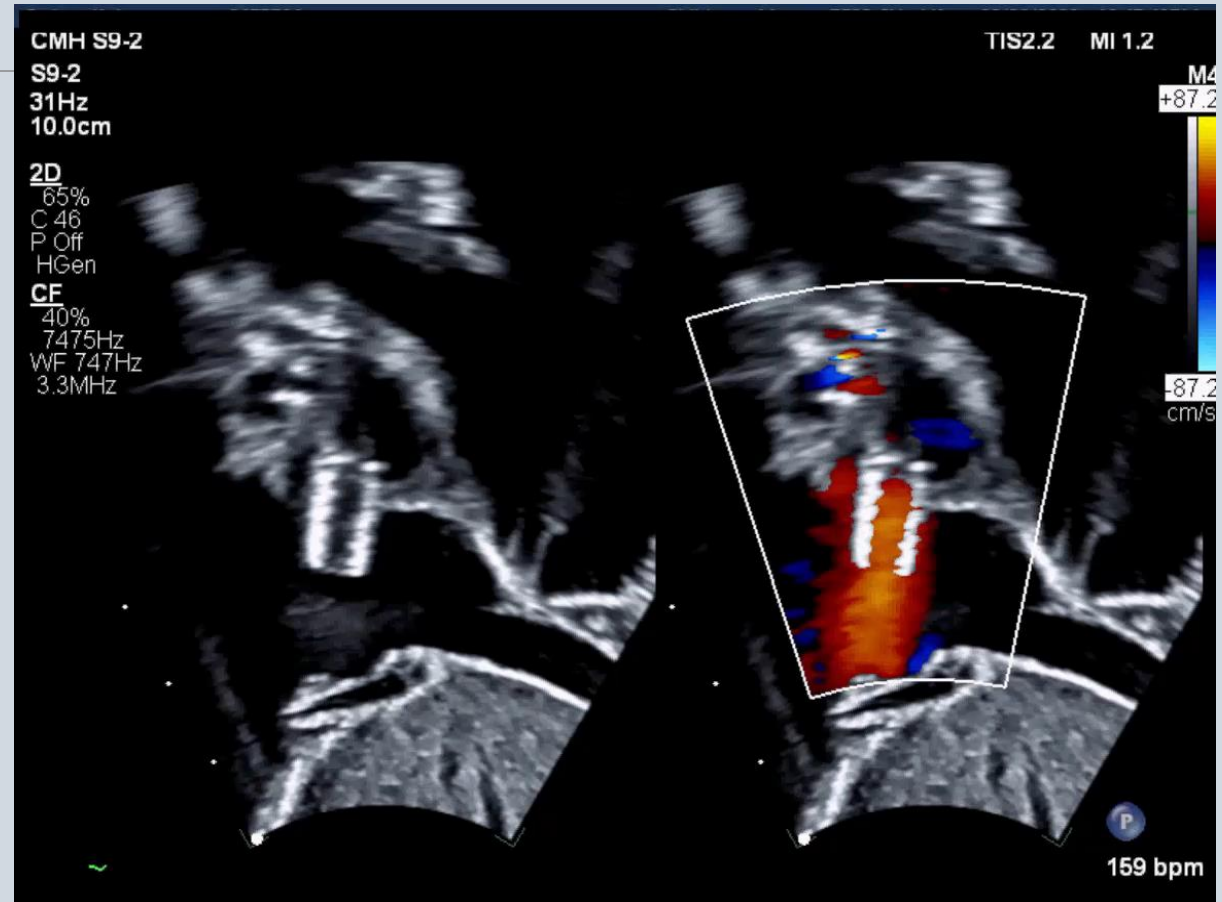
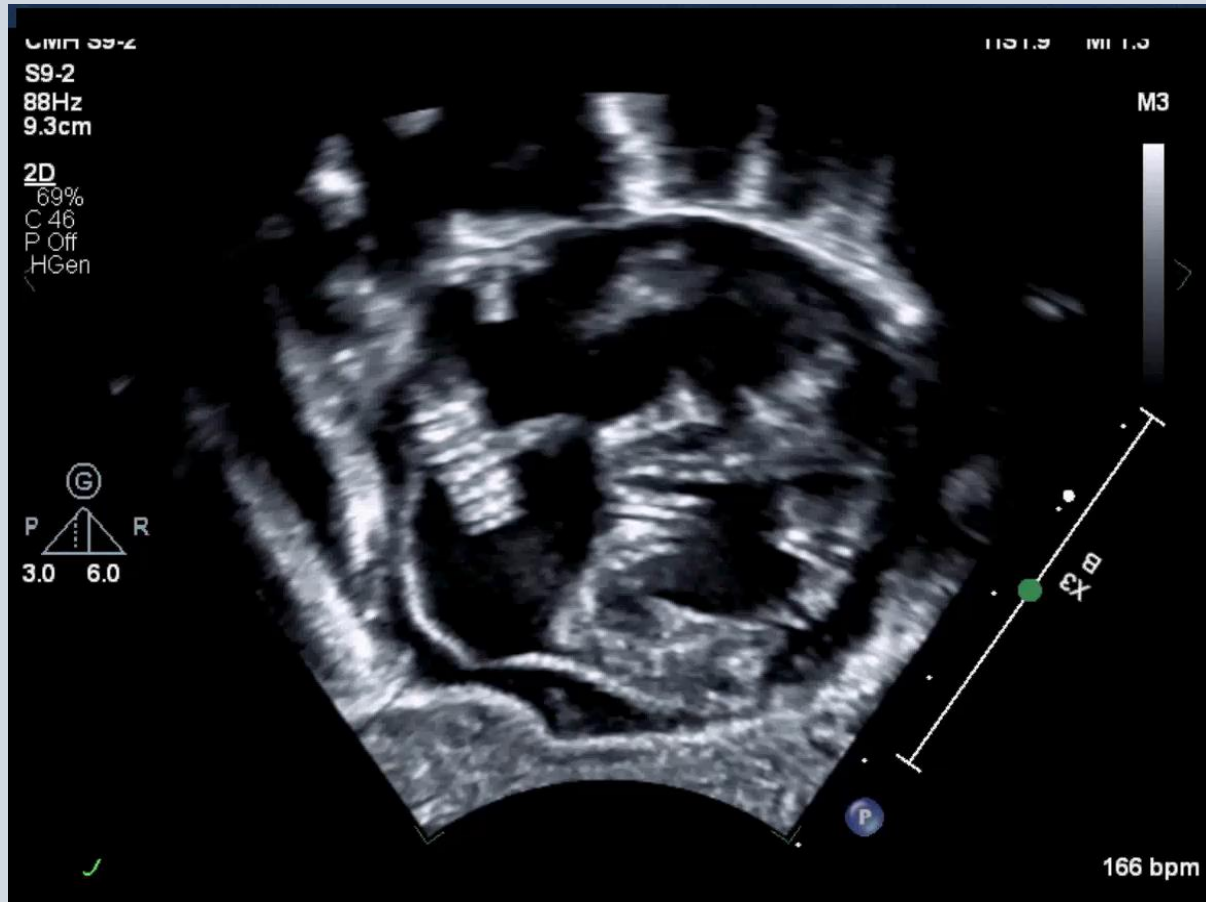
# Hybrid procedure

Stage I Hybrid (PDA stent, Bilateral Pulmonary artery (PA) bands, and ASD stent) for HLHS



- Placement of PA bands
  - Balances circulation to the lungs and body
- PDA stent
  - Keeps the PDA open and maintains the connection to the aorta and the body's circulation
- Atrial septostomy or stenting of PFO
  - To provide open blood flow and mixing of the oxygenated and deoxygenated blood between the atria



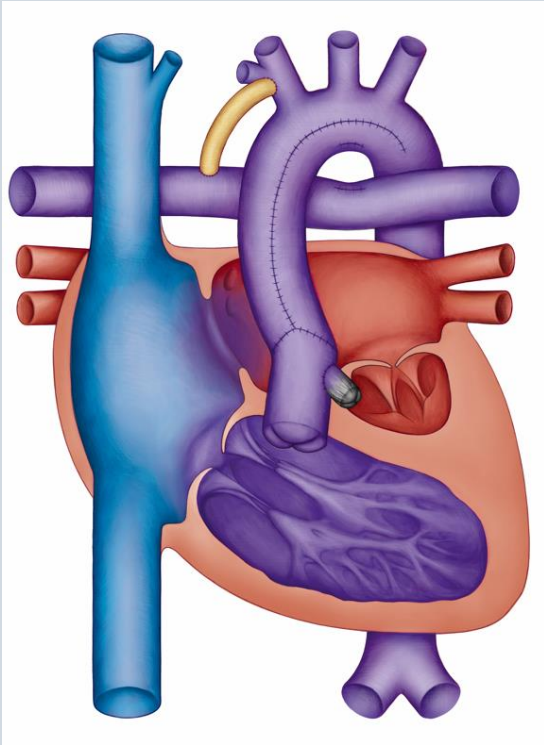




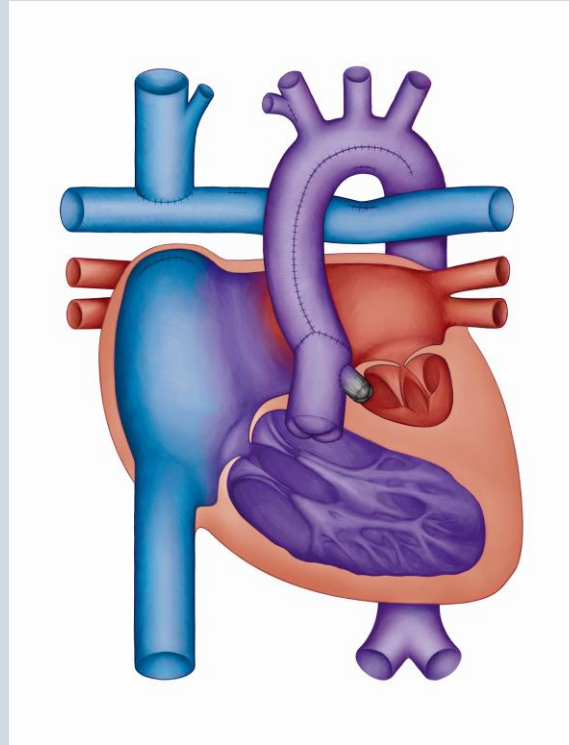
# The single ventricle

---

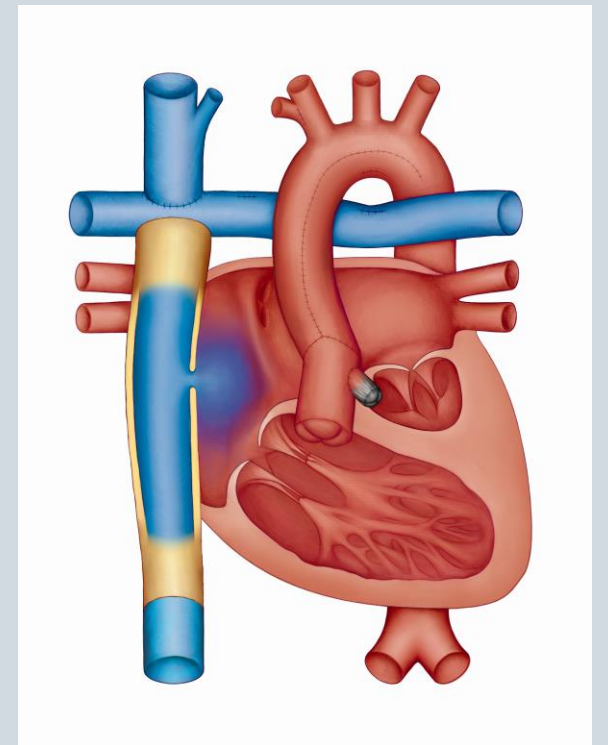
Norwood/shunt



Bidirectional Glenn 4-6 months



Fontan palliation 2-3 years



# Helpful resources

---

- Dr. Nitin Madan's prior talk on hypoplastic left heart syndrome
  - August 2021 education series talk
- Anticipation, Accompaniment, and a Good Death in Perinatal Care
  - Bryanna S. Moore , Brian S. Carter, Bryan Beaven, Katie House, and Joel House



# Summary

---

- Prenatal detection is extremely important in the diagnosis of aortic stenosis
  - Aortic stenosis has multiple avenues it can evolve into, and time is of the essence for these fetuses
- Prenatal care and consults give patients time to help determine the route and pathway patient will go down whether they choose fetal intervention, post natal surgery or comfort care
  - Mentally prepares patient for whatever decision they make
- Ultrasound imaging is very important piece in patient care, early detection and monitoring can make a huge difference in decisions



Thank YOU!! And Happy Valentines Day!

CONTACT: ALISON SAMRANY [AMSAMRANY@CMH.EDU](mailto:AMSAMRANY@CMH.EDU)

---

Echocardiography in pediatric and congenital heart disease: from fetus to adult

Lai, Wyman W. 2009

Predictive Value of Fetal Pulmonary Venous Flow Patterns in Identifying the Need for Atrial Septoplasty in the Newborn With Hypoplastic Left Ventricle

- Erik Michelfelder, MD; Carlen Gomez, MD; William Border, MBChB; William Gottliebson, MD; Cheri Franklin, CNP

Fetal Aortic Valve Stenosis and the Evolution of Hypoplastic Left Heart Syndrome

Patient Selection for Fetal Intervention

Kaarin Mäkikallio, Doff B. McElhinney, Jami C. Levine, Gerald R. Marx, Steven D. Colan, Audrey C. Marshall, James E. Lock, Edward N. Marcus and Wayne Tworetzky